

Original Article

Determination of Sex using Discriminant Function Analysis in Young Adults of Nashik: A Lateral Cephalometric Study

Ruchi U. Mathur, Aarti M. Mahajan, Rishikesh C. Dandekar, Rahul B. Patil
Dept of Oral Pathology and Microbiology, MGVS K.B.H Dental College, Nashik

Corresponding Author:

Dr Ruchi Mathur

Address: 7/B, Tulsi chaya,
Talao road, Bhayander (E),
Mumbai-401105

E-mail: drruchimathur@yahoo.com

Received: 12-10-2013

Revised: 10-11-2013

Accepted: 20-12-2013

Abstract

Aim: To test the validity of sex discrimination using lateral cephalometric radiography and discriminant function analysis in young adults and to set certain population- specific standards for the same.

Settings and design: Lateral cephalograms of 30 male and 30 female patients visiting the OPD of MGVS K.B.H Dental College and Hospital, Nashik having a normal occlusion were included in the study.

Methods and materials: Lateral cephalograms were obtained in a standard position with teeth in centric occlusion and lips relaxed. Each radiograph was traced and cephalometric landmarks were determined with the help of a good viewer. Calculations of 11 cephalometric measurements were performed.

Statistical analysis: Descriptive statistics including means, standard deviations, and coefficient of variations were calculated for all the variables. The cephalometric data was treated using Minitab computer program.

Results: 4 linear and 2 angular measurements were significantly different between the genders, indicating the presence of sexual dimorphism in the skull.

Conclusion: With discriminant function derived by using all the 11 variables simultaneously the sex was determined correctly in 93% of the cases. Out of 11 variables studied, 4 variables were more reliable in determining sex of the adolescent population of Nashik.

Keywords: Legal medicine, anthropology, Sex determination, Lateral cephalometrics, Discriminant function analysis.

This article may be cited as: Mathur RU, Mahajan AM, Dandekar RC, Patil RB. Determination of Sex using Discriminant Function Analysis in Young Adults of Nashik: A Lateral Cephalometric Study. J Adv Med Dent Scie 2014;2(1):21-25.

Introduction

In today's world where crime, murders, accidents rule the roost, investigative measures and techniques should not only be precise but also competent enough to bring the culprit to the book.¹ In this context, forensic medicine and forensic investigative methods need to be underlined in red

Determination of sex and estimation of stature of a subject is one of the most important aspect of medicolegal cases and anthropological research.¹ Sex determination is the keystone in determining the biological profile of an individual and this classification effectively cuts the number of possible matches in half.² Identification techniques such

as facial reconstruction would be impossible if sex is not correctly established. Thus, isolating, interpreting and quantifying the manifestations of sex form an essential part of all skeletal analyses.² Unfortunately, this is often not a simple process since male and female attributes span a continuum of morphologic configurations and metric measures in the skeleton.² Sex determination based on skeletal features therefore plays a crucial role in legal medicine and forensic anthropology.³

Next to the pelvis, the skull is the most easily sexed part of the skeleton.⁴ As a general rule, the skeleton does not manifest definitive sexual traits until after the full development of the secondary sex characteristics that appear during puberty.³

In establishing the identity of sex from a defleshed skull, lateral cephalograms and posteroanterior view radiographs assume a predominant role, as they can provide architectural and morphological details of the skull, thereby revealing additional characteristics and multiple points for comparison.⁵ Various workers have claimed that the identification of sex by skull radiographs is a reliable method which provides accuracy up to 80–100%.³

Forensic norms have been set up for many ethnic and racial groups in many studies; differences among races and ethnic groups have been proven, and standard norms have been developed.⁶ Information on cephalometric norms for a population has tremendous value in forensic dentistry. Cephalometric standards allow identification of race and gender of victims using simple measurements.⁶

The objective of this study was therefore, to test the validity of sex discrimination using lateral cephalometric radiography and discriminant function analysis in young adults visiting our College and Hospital and to set

certain population- specific standards for the same.

Materials and Methods

Sixty patients visiting the OPD of our Dental College and Hospital, having a normal occlusion met the study criteria. An informed consent was taken to include their cephalometric radiographs in this study. Lateral cephalograms were obtained in a standard position with teeth in centric occlusion and lips relaxed.

The sample included an equal number of males and females with mean age of 20.2 ± 2.89 and 19.5 ± 3.39 years, respectively.

Each radiograph was traced and cephalometric landmarks were determined with the help of a good viewer. (**Figure 1**)

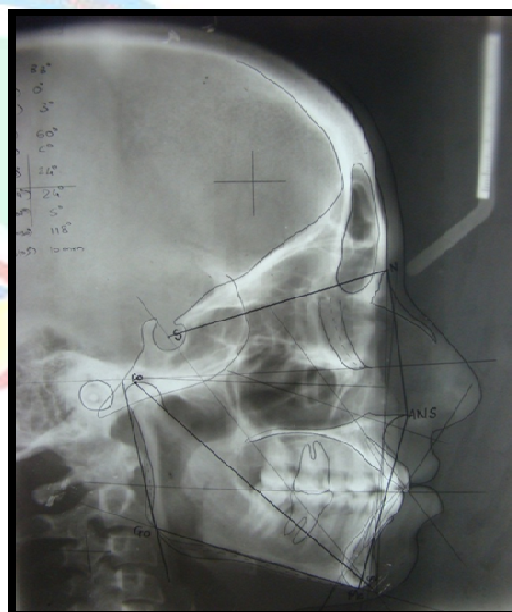


Figure 1: Showing the cephalometric landmarks traced.

S – sella, Co- condylon, N- nasion, ANS- anterior nasal spine, Me- menton, Go- gonion

We chose the nasion to sella (N - S) line and the Frankfurt horizontal (FH) plane as

reference lines and planes, commonly used in lateral cephalometric analyses.⁶

Calculations of 11 cephalometric measurements were performed (**Table 1**).

Descriptive statistics including means, standard deviations, and coefficient of variations were calculated for all the variables. The values derived were compared between both the sexes using Student's t test. Significance was set at $p < 0.05$ value. The cephalometric data was treated using Minitab computer program. Discriminant function was derived for variables and discriminant score was then calculated for individuals.^{3,7}

This study selected the most adequate measurements that are statistically validated and clinically relevant.

Table 1: The 11 cephalometric variables measured in this study

Linear Variables	Angular Variables
Nasion- Sella (N-S)	Sella-Nasion-Point A (SNA)
Menton-Gonion (Me-Go)	Sella-Nasion-Point B (SNB)
Nasion-Anterior nasal spine (N-ANS)	Point A-Nasion-Point B (ANB)
ANS- Menton (ANS-Me)	Gonial angle
Conylon-Gnathion (Co-Gn)	Mandibular plane angle (Mand pl angle)
Projection of sella on Frankfurt's Horizontal (FH)- Projection of Condylon on FH (S'-Co')	

Results

Table 2 and 3 show the descriptive statistics of the 11 cephalometric variables from the sample of 60 young adults of Nashik. As indicated from the observations, 4 linear and 2 angular measurements were significantly different between the genders, indicating the presence of sexual dimorphism in the skull.

Mean male values for all linear and angular skeletal parameters were larger than the mean female values except for two angular parameters namely, gonial angle and mandibular plane angle, which were significantly larger than mean male values.

For stepwise discriminant function analysis, this study used the Minitab computer program to select a combination of measurements that best determine sex from the data entered.

Table 2: Showing the descriptive statistics for the linear measurements among male and female groups

Variables	Units	Male	Female	t value	p value
		Mean	Mean		
Age	Yrs	20.2	19.5		
N-S	mm	73.33 3	70.833	3.348	0.001*
Me- Go	mm	73.46 6	70.733	2.091	0.041*
N - ANS	mm	53.73 3	50.716	3.065	0.003*
ANS-Me	mm	68.78 3	68.233	0.325	0.746
Co- Gn	mm	119.8 66	113.983	3.059	0.003*
S' - Co'	mm	18.61 6	14.9	1.71	0.093

α degree of freedom- 58

Table 3: Showing the descriptive statistics for the angular measurements among the male and female groups

Variables	Units	Male	Female	t value	p value
		Mean	Mean		
Age	Yrs	20.2	19.5		
SNA	deg	81.316	80.4	0.905	0.369
SNB	deg	77.35	77	0.374	0.71
ANB	deg	3.9	3.6	0.527	0.6
Gonial angle	deg	119.96	124.766	-2.459	0.017*
Mand pl angle	deg	24.533	28.133	-2.306	0.025*

α degree of freedom- 58

The computer program selected the 4 best variables out of the 6 significant measurements in stepwise analysis.

Discussion

Sex determination based on skeletal features plays a crucial role in legal medicine and forensic anthropology as in many cases, only skull is available for the forensic examination after death and hence determination of sex and stature from skull would be of great significance in establishing the identity of a person in a medicolegal case.⁴

Researchers have proposed two approaches, morphological (nonmetrical) and metrical, for the determination of sexual characteristics from bones.³ Since morphological attributes are more subjective and sex determination depends on the experience of the investigator, inexperienced workers are likely to make inaccurate assessment of sex based using visual methods. However, combining these two approaches improves accuracy, as they complement each other.³ Also, the technique of discriminant function analysis overcomes some of the problems inherent in subjective methods of sexing skulls, providing a relatively simple, objective means of sexing material with a calculable reliability.^{3,7}

Till today, discriminant function for the determination of sex has not been derived specifically for the population of Nashik. As differences exist in various races as regards of sexual differentiation, what may be true for one human group may not be necessarily true for another, and the discriminant function technique was therefore applied for sexing skulls from various adolescents to establish their specific standards of assessment.^{3,7}

In the present study, 11 cephalometric measurements were used in discriminant function analysis and they provided very good sex discrimination in the subjects of known sex. In this study, men showed significantly larger measurements for 4 linear skeletal

parameters namely, N-S, Menton-Gonion(Me-Go), Nasion-Anterior nasal spine(N-ANS) and Condylon-Gnathion(Co-Gn) whereas females had larger measurements for 2 angular parameters namely, Gonial angle and Mandibular plane angle at $p < 0.05$. However, all other parameter differences were non-significant between the two genders. Hsiao TH et al attempted to develop a new method to determine sex from the skull with lateral radiographic cephalometry and discriminant function analysis. With discriminant function created from 18 cephalometric variables the sex was determined with 100% accuracy in a random sample of 100 Taiwanese adults (50 male and 50 female).³ In a study by Patil and Mody (2005), with discriminant function derived by using 10 cephalometric variables simultaneously, in 99% of cases sex could be determined correctly.⁷ Veyre - Goulet et al. (2008) showed that sex could be determined with 95.6% accuracy in a sample of 114 adult dry skulls of European population using discriminant function derived from the 18 cephalometric measurements.⁷

Thus we can state here that skull sexing methods using lateral cephalographs with discriminant function analysis seem always suitable, but the most indicative variables differ relative to the ethnic population concerned.^{3,7}

Conclusion

From this study, the following conclusions can be made: With discriminant function derived by using all the 11 variables simultaneously, in 93% of the cases, sex was determined correctly. Out of 11 variables studied, 4 variables, i.e. N-S, N-ANS, Co-Gn & Gonial angle were more reliable while the remaining 7 were found to be less reliable in determining sex of the young adults of Nashik.

To summarize, this study selected 4 routinely assessed cephalometric measurements as the

minimum number of traits required to obtain the maximum discriminant effectiveness of sex determination in young adults of Nashik. Our results will therefore be useful among both genders in forensic dentistry for identification purposes.

In future, this discriminant method should be tested on greater populations with a diverse age group to confirm its reliability.

References

- 1.İşcan M.Y. Global forensic anthropology in the 21st century. *Forensic Sci. Int.* 2001; 117: 1–6.
- 2.Loith S.R. Sex determination. In *Encyclopedia of forensic sciences*, Jay Siegel (editor). Vol 1-3.Elsevier
- 3.Tin-Hsin Hsiao et al. Sex determination using discriminant function analysis in children and adolescents: a lateral cephalometric study. *Int J Legal Med* 2010 124:155–160.
- 4.Walker P.L. Sexing skulls using discriminant function analysis of visually assessed traits. *Am J Phys Anthropol.*2008; 136: 39–50.
- 5.Biggerstaff R.H. Craniofacial characteristics as determinants of age, sex and race in forensic dentistry. *Dent Clin North Am*1977;21 (1): 85–97.
- 6.Ayoub F. Forensic norms of female and male lebanese adults. *J Forensic Odontolstomatol* 2008; 27 (1): 18-23.
- 7.Patil K.R, Mody R.N. Determination of sex by discriminant function analysis and stature by regression analysis: a lateral cephalometric study. *Forensic Scie Int* 2005;147(2-3):175-180.

Source of support: Nil

Conflict of interest: None declared