

ORIGINAL ARTICLE

SEX DETERMINATION BY USING MANDIBULAR RAMUS - A FORENSIC STUDY

Tejashree Bhagwatkar¹, Manjiri Thakur², Devendra Palve³, Apoorva Bhondey¹, Yogita Dhengar¹, Swati Chaturvedi¹

¹Post Graduate Student, Professor and Head², Professor³

Department of Oral Pathology and Microbiology, Swargiya Dadasaheb Kalmegh Smruti Dental College and Hospital, Nagpur, Maharashtra, India

ABSTRACT:

Introduction- Sex determination is first step for identification followed by age and stature estimation as both are sex dependent. Mandible becomes important source for sex confirmation in absence of complete pelvis as mandible is considered as most durable facial bone that retains its shape better than others. Panoramic radiography is widely used method for obtaining a comprehensive overview of the maxillofacial complex. **Aim and objectives-** 1. To evaluate various measurements of mandibular ramus on digital orthopantomographs. 2. To assess the usefulness of mandibular ramus in sex determination. **Materials and methods-** A retrospective study was conducted using orthopantomograph of 100 subjects (50 males and 50 females). Orthopantomograph were taken by Sirona XP Digital Panoramic Machine (69 kVp 15mA 14.1 sec). The data were analyzed using linear discriminant analysis of the statistical package STATA 13.0. **Results-** It was found that all variable of mandibular ramus on orthopantomographs was statistically significant p-value <0.01. **Conclusion-** Mandibular ramus is useful aid for sex determination as it is readily available and resistant to any disintegration process.

Key words- Mandibular ramus, orthopantomograph, linear discriminant analysis

Corresponding Author- Dr. Tejashree Bhagwatkar, 1Post Graduate Student, Department of Oral Pathology and Microbiology, Swargiya Dadasaheb Kalmegh Smruti Dental College and Hospital, Nagpur, Maharashtra, India, E mail: dr.tejashree12@gmail.com

This article may be cited as: Bhagwatkar T, Thakur M, Palve D, Bhondey A, Dhengar Y, Chaturvedi S. Sex determination by using Mandibular Ramus - A Forensic Study. J Adv Med Dent Scie Res 2016;4(2):1-6.

INTRODUCTION

Sex determination is first step for identification followed by age and stature estimation as both are sex dependent.¹ To identify sex in explosions, mass disaster, air hurricanes from decayed and damaged dead bodies (non living) is the most challenging task for forensic experts.² It has been carried out by many methods, morphological assessment was considered as oldest approach in forensic odontology and medico-legal cases. Depending upon the available bones and their condition the methods varies for determination of sex.³

The pelvis and skull are the most reliable source among human bones. Mandible becomes important source for sex confirmation in absence of complete

pelvis as mandible is considered as most durable facial bone that retains its shape better than others.⁴ Mandible is the largest, strongest and movable part of the skull.⁵ They are extremely durable in fire and bacterial decomposition makes them invaluable for identification.²

The mandibular ramus is quadrilateral, and has two surfaces, four borders and two processes. The lateral surface is relatively featureless.⁶ Radiography is commonly accessible, less invasive and is used in routine procedures.⁷ Panoramic radiography is widely used method for obtaining a comprehensive overview of the maxillofacial complex.⁸

AIM AND OBJECTIVES

- 1) To evaluate various measurements of mandibular ramus on digital orthopantomographs.
- 2) To assess the usefulness of mandibular ramus in sex determination.

MATERIALS AND METHODS

A retrospective study was conducted using orthopantomograph of 100 subjects (50 males and 50 females). Their ages ranged from 20 to 40 years. Ideal orthopantomographs were selected for the study. Pathological, fractured, deformed and developmental disturbances of the mandible were excluded from the study. Orthopantomograph were taken by Sirona XP Digital Panoramic Machine (69 kVp 15mA 14.1 sec). This study was performed on radiographs stored in the system so ethical clearance was not required. All mandibular ramus measurements were carried out using Sidex software.

Five parameters were measured using mouse driven method (by drawing lines using mouse on chosen points on digital orthopantomographs) (Figure 1)

1. Maximum ramus breadth (Mx RB) - Distance between most anterior and line connecting most posterior part of condyle and angle of jaw.
2. Minimum ramus breadth (Mi RB) - Distance between smallest anterior to posterior of ramus.
3. Condylar height/ Maximum ramus height (Mx RH) - Height of ramus from most superior part

on condyle to the tubercle or most protruding portion of the inferior border of the ramus.

4. Projective height of ramus (PH) - Distance between highest part of condyle and lower margin of mandible.

5. Coronoid height (CH) - Projective distance between coronion to lower margin of mandible.

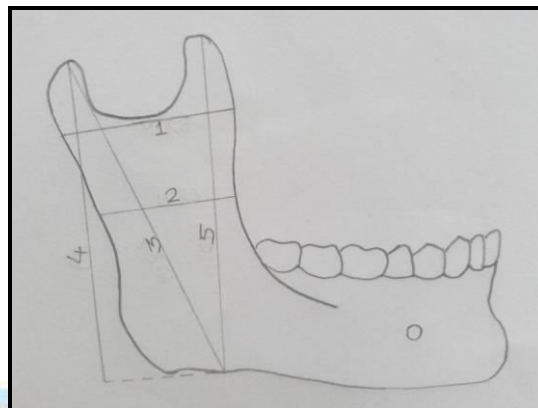


Figure 1: Diagram showing mandibular ramus measurements

STATISTICAL ANALYSIS

The data were analyzed using linear discriminant analysis of the statistical package STATA 13.0. Discriminant function analysis was used to determine variables that discriminate between male and female.

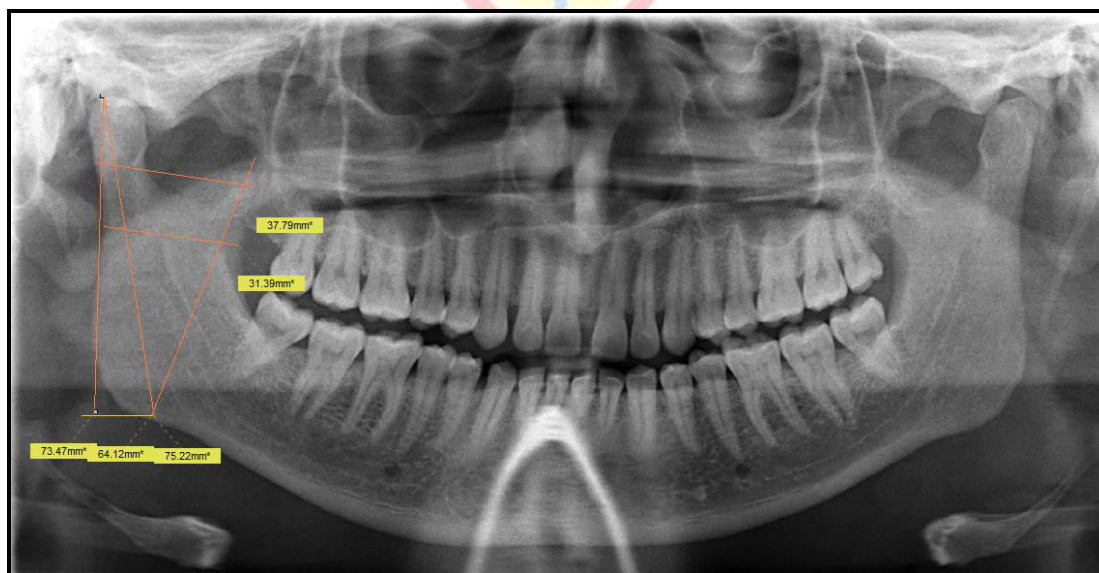


Figure 2: Measurements of mandibular ramus on orthopantomographs

RESULTS

Descriptive statistics of all five mandibular ramus measurements for both sexes are shown in Table 1. It has been found that each variable was significant p value <0.01. Mean measurements between males and females for right and left side are shown in figure 3 and figure 4, while mean measurements between both sexes for both sides are shown in figure 5.

The sex could be determined from calculations using the equation given below (Table 3)

For right side

$$D_{(Male)} = -511.92 + 1.326 (\text{Max ramus breadth}) + 6.18 (\text{Min ramus breadth}) + 3.827 (\text{Condylar height}) + 6.606 (\text{Projective height of ramus}) - 0.297 (\text{Coronoid height})$$

$$D_{(Female)} = -469.361 + 0.855 (\text{Max ramus breadth}) + 6.024 (\text{Min ramus breadth}) + 3.697 (\text{Condylar height}) + 6.47 (\text{Projective height of ramus}) - 0.286 (\text{Coronoid height})$$

For left side

$$D_{(Male)} = -507.727 + 1.655 (\text{Max ramus breadth}) + 5.435 (\text{Min ramus breadth}) + 4.944 (\text{Condylar height}) + 3.093 (\text{Projective height of ramus}) + 2.294 (\text{Coronoid height})$$

$$D_{(Female)} = -471.231 + 1.177 (\text{Max ramus breadth}) + 5.427 (\text{Min ramus breadth}) + 4.797 (\text{Condylar height}) + 3.027 (\text{Projective height of ramus}) + 2.278 (\text{Coronoid height})$$

$$D_{(Female)} = -475.805 + 0.894 (\text{Max ramus breadth}) + 6.182 (\text{Min ramus breadth}) + 4.578 (\text{Condylar height}) + 4.663 (\text{Projective height of ramus}) + 0.729 (\text{Coronoid height})$$

Both Right and left side

$$D_{(Male)} = -515.861 + 1.406 (\text{Max ramus breadth}) + 6.254 (\text{Min ramus breadth}) + 4.723 (\text{Condylar height}) + 4.76 (\text{Projective height of ramus}) + 0.718 (\text{Coronoid height})$$

$$D_{(Female)} = -475.805 + 0.894 (\text{Max ramus breadth}) + 6.182 (\text{Min ramus breadth}) + 4.578 (\text{Condylar height}) + 4.663 (\text{Projective height of ramus}) + 0.729 (\text{Coronoid height})$$

For classifying a given sample as male or female, higher/ maximum of two equations from both sexes was considered. In this study, cut score was found to be 0. Values greater than this cut score considered as male and lesser than this considered as female.

When all variables were considered, 87% of the cases were classified correctly for right side, while it was 76% for left side and 84% on both sides.

Table 1- Descriptive statistics

Variable	Mean and Standard deviation					
	Male			Female		
	Right	Left	Mean	Right	Left	Mean
Max Ramus breadth	41.97±3.24	42.05±3.12	42.01±3.05	37.18±2.52	37.88±2.56	37.53±2.48
Min Ramus breadth	32.95±2.61	33.08±3.32	33.02±2.80	31.18±2.57	31.96±2.38	31.57±2.43
Condylar height	76.38±4.37	77.28±4.18	76.83±4.22	73.13±1.84	74.47±2.19	73.80±1.94
Projective height of ramus	74.24±3.81	74.68±4.36	74.46±4.04	71.92±1.53	72.80±1.48	72.36±1.42
Coronoid height	65.98±4.97	66.07±3.91	66.02±4.39	62.91±2.58	63.39±2.40	63.39±2.40

Table 2- Tests of equality

Variable	Wilk's Lambda			F-value			p-value		
	Right	Left	Mean	Right	Left	Mean	Right	Left	Mean
Max Ramus breadth	0.59	0.64	0.6	28.04	23.72	15.29	<0.01	<0.01	<0.01
Min Ramus breadth	0.89	0.96	0.9	11.78	13.76	7.64	<0.01	<0.06	<0.01
Condylar height	0.80	0.84	0.82	23.49	17.73	21.32	<0.01	<0.01	<0.01
Projective height of ramus	0.86	0.92	0.89	15.90	8.29	12.00	<0.01	<0.01	<0.01
Coronoid height	0.86	0.89	0.87	14.99	11.88	13.94	<0.01	<0.01	<0.01

Table 3- Linear discriminant function

Variable	Right		Left		Mean	
	Male	Female	Male	Female	Male	Female
Constant	-511.92	-469.361	-507.727	-471.231	-515.861	-475.805
Max Ramus breadth	1.326	0.855	1.655	1.177	1.406	0.894
Min Ramus breadth	6.18	6.024	5.435	5.427	6.254	6.182
Condylar height	3.827	3.697	4.944	4.797	4.723	4.578
Projective height of ramus	6.606	6.47	3.093	3.027	4.76	4.663
Coronoid height	-0.297	-0.286	2.294	2.278	0.718	0.729

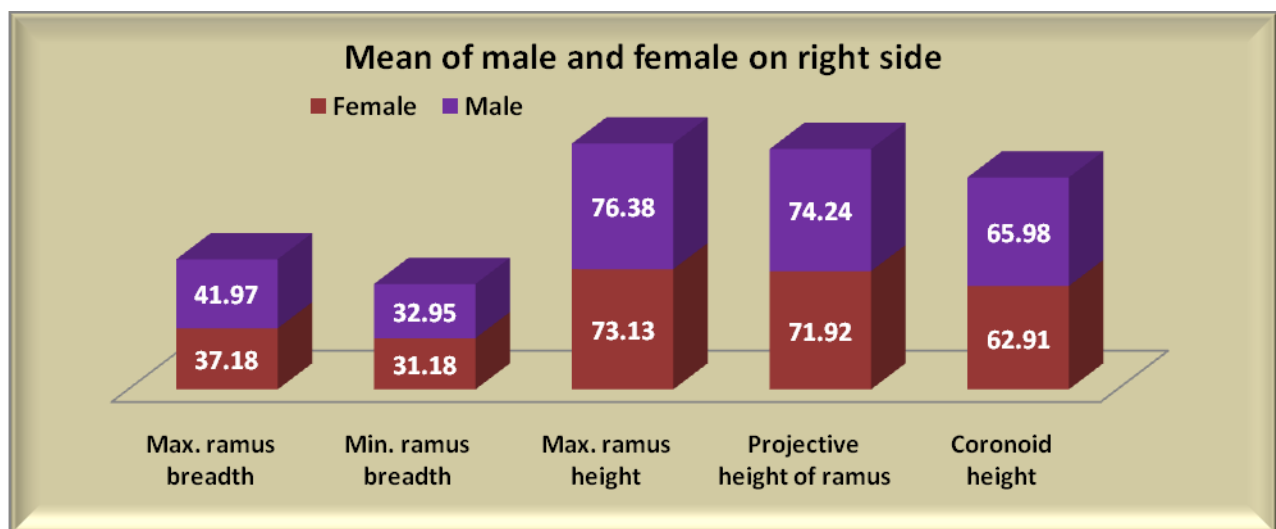


Figure 3: Mean of male and female on right side

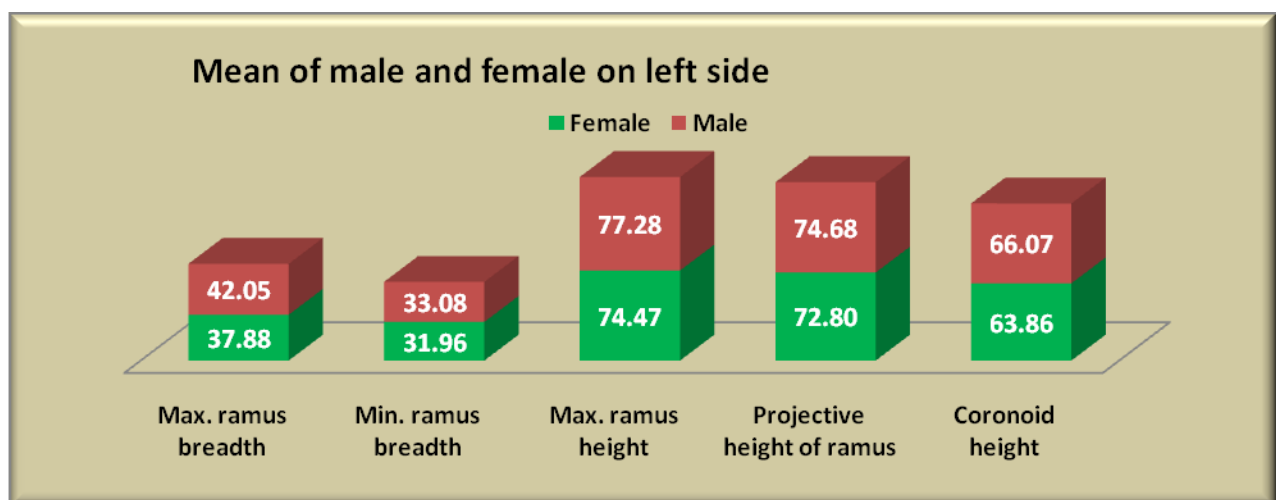


Figure 4: Mean of male and female on left side

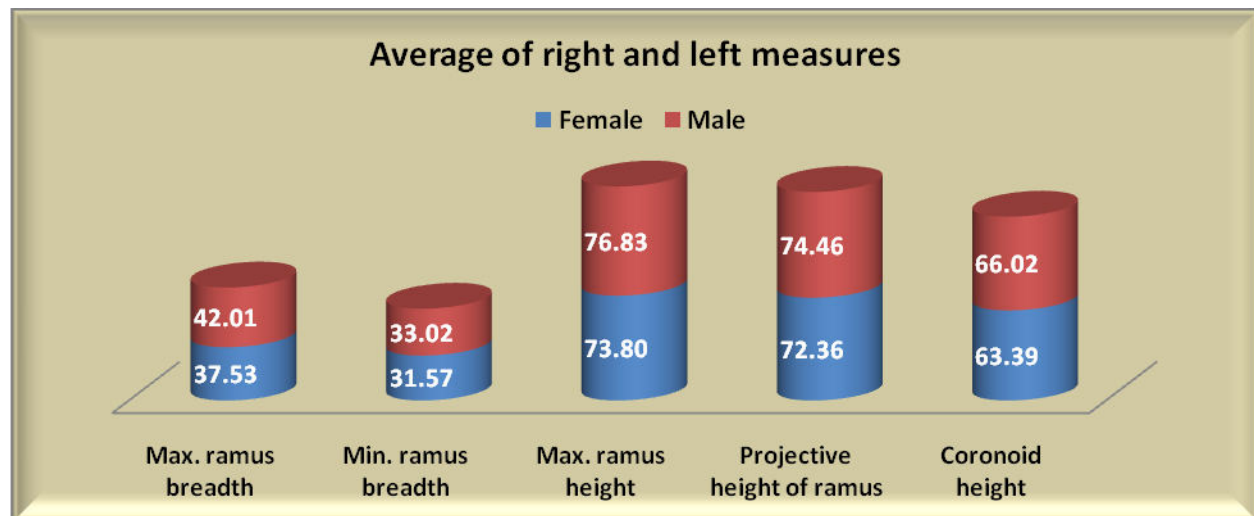


Figure 5: Mean of male and female on both sides

DISCUSSION

Determination of sex is a very important part of study in Anthropology and forensic science, as further investigations will be based on it.⁹ Mandibles can be used for sexual dimorphism as it is reliable. Orthopantomograph used widely and routinely used by the clinicians for the diagnosis of oral diseases.

In present study, mandibular ramus measurements were subjected to linear discriminant analysis. It has been found all five variables measured on mandibular ramus using orthopantomograph showed statistically significant sex difference between sexes. This shows mandibular ramus expresses strong sexual dimorphism. And the accuracy varies as per sides, for right side 87%, left side 76% and for both sides its 84%.

Our results were similar with Indira AP et al (2012), they found statistically significant mandibular ramus measurements with over all accuracy of 76%.

Saini V et al (2011) conducted a study on dry mandible in North Indian population. They found that mandibular ramus express strong sexual dimorphism. The overall prediction rate is 80.2% for all five variables.

Various studies has been carried out on dry mandible Vijay G (2013)⁹ and Hoque MM et al (2014)⁶ for determination of sex. Other studies has been conducted to investigate sexual dimorphism of the mandibular ramus flexure according to Hill (2000)¹⁰, Haun (2000)¹¹ and Balci et al (2005)¹² and found that results were contradictory.

It has been found that there are many factors which influence the development and thus the appearance

of bones. The most common is socio-environmental factors such as nutrition, food, climate, pathologies etc.¹³ There may be slight difference in pattern of bone is variable population.

CONCLUSION

Mandibular ramus is useful aid for sex determination as it is readily available and resistant to any disintegration process. Orthopantomographs found to be reliable when all mandibular ramus measurements were carried out for determination of sex.

REFERENCES

1. Scheuer L. Application of osteology to forensic medicine. Clin Anat 2002;15:297-312.
2. Srivastava PC. Correlation of odontometric measures in sex determination. J Indian Acad Forensic Med 2011;32(1):56-61.
3. Raj JD, Ramesh S. Sexual dimorphism in mandibular ramus of South Indian population. Actrocom Online J Anthro 2013;9(2):253-258.
4. Hu KS, Koh KS, Han SH, et al. Sex determination using nonmetric characteristics of the mandible in Koreans. J Forensic Sci 2006;51(6):1376-82.
5. Tanveer Ahamed Khan H.S J.H Sharieff. Observation on morphological features of human mandibles in 200 South Indian subjects. Anatomica Karnataka 2011;5(1):44-49.
6. Hoque MM, Ara S, Begum S, et al. Morphometric analysis of dry adult human mandibular ramus. Bangladesh J Anat 2014;12(1):14-16.
7. Juodzbalys G, Wang HL, Sabalys G. Anatomy of mandibular vital structure. Part II: Mandibular incisive

- canal, mental foramen and associated neurovascular bundles in relation with dental implantology. J Oral Maxillofac Res 2010;1(1):2-10.
8. Schulze R, Krummenauer F, Schalldach F, et al. Precision and accuracy of measurements in digital panoramic radiography. Dentomaxillofacial Radio 2000;29:52-56.
 9. Vinay G, Gowri M, Anbalagan J. Sex determination of human mandible using metrical parameters. J Clin Diagnostic Res 2013;7(12):2671-2673.
 10. Hill CA. Technical Note: Evaluating mandibular ramus flexure as a morphological indicator of sex. Am J Phys Anthropol 2000;111:573-7.
 11. Haun, S. J. Brief communication: a study of the predictive accuracy of mandibular ramus flexure as a singular morphologic indicator of sex in an archaeological sample. Am. J. Phys. Anthropol 2000;111(3):420-32.
 12. Balci Y, Yavuz, M. F, Cagdir, S. Predictive accuracy of sexing the mandible by ramus flexure. Homo 2005;55(3):229-37.
 13. Suazo GIC, Pedro SVJ, Schilling QN, et al. Ortopantomographic blind test of mandibular ramus flexure as a morphological indicator of sex in Chilean young adults. Int. J. Morphol 2008;26(1):89-92.



Source of support: Nil

Conflict of interest: None declared

This work is licensed under CC BY: *Creative Commons Attribution 3.0 License.*