

CASE REPORT

MANAGEMENT OF VERTICAL FRACTURE OF A DECIDUOUS TOOTH – A CASE REPORT

Bhavna H Dave, Devanshi N Mehta, Seema S Bargale, Poonacha KS

Department of Paedodontics & Preventive Dentistry, K.M Shah Dental College & Hospital, Piparia, Vadodara, Gujarat

ABSTRACT:

Background:- A replacement of a missing deciduous tooth is of importance to provide aesthetics, function, comfort, self confidence and overall well being of a pediatric patient. This article reports a case in which a composite pontic is used as a replacement option for the missing crown of the fractured deciduous tooth which is bonded on either side of the missing tooth using fibre reinforced composite. **Methods:-** A composite tooth was used as a pontic which was bonded to the adjacent teeth using a bondable, reinforcing polyethylene fibre, along with preservation of the root of the deciduous tooth. **Results:-** Aesthetics obtained as a result were satisfactory for the patient and the parent. **Conclusion:-** After three months of clinical use, a single-tooth replacement using the composite tooth pontic provided acceptable aesthetics and function. Polyethylene fibers appeared to have best properties so as to be used in such a scenario. Along with ease of application fiber can be used alternative to traditionally used materials in the management of such cases.

Key words: Vertical fracture, Deciduous tooth, Aesthetic replacement, Composite pontic.

Corresponding Author: Dr. Devanshi Mehta, 10/56, Ellora Park, Nr. Race Course Circle, Subhanpura, Vadodara, Gujarat-390023.

This article may be cited as: Dave BH, Mehta DN, Bargale SS, KS Poonacha. Management of vertical fracture of a deciduous tooth – A case report. J Adv Med Dent Scie Res 2016;4(2):63-66.

INTRODUCTION

‘A smile of a child is packaged sunshine and rainbows’.

Healthy oral cavity is a key requisite for beautiful looks. Facial deformity may be a ‘social disability’, as its impact is not only on the individual, but is noticed by others. The impact of missing anterior teeth during early childhood can be harmful so its replacement is essential. In addition, aesthetic appearance and longevity of the restorative material plays an important role in its acceptance for dentists, patients and parents.

This case report enlightens a different way to replace a fractured deciduous crown in a pediatric patient using fibre reinforced composite.

CASE REPORT

A five year old child reported to the Department of Paedodontics & Preventive Dentistry with a complaint of broken front tooth. [Figure 1]

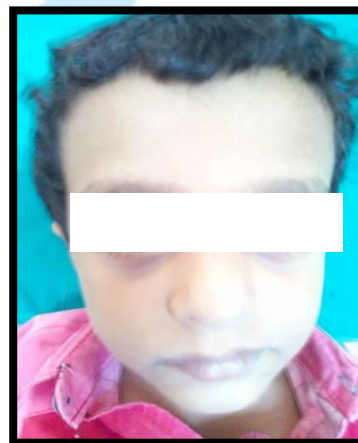

Figure 1: Extraoral photograph of the patient

On eliciting a detailed history, the trauma had taken place 2 days back by a direct hit of a bike handle. Patient gave positive history of soft tissue swelling of the upper lip and pain on mastication only on the day of the trauma. On clinical examination, crown of maxillary right deciduous canine (53) was fractured in a vertical manner dividing the crown into two

segments. The segments were grade III mobile with discolouration on the palatal surface and no sign of bleeding, swelling or pain in the region of the tooth on the day of examination. [Figure 2]

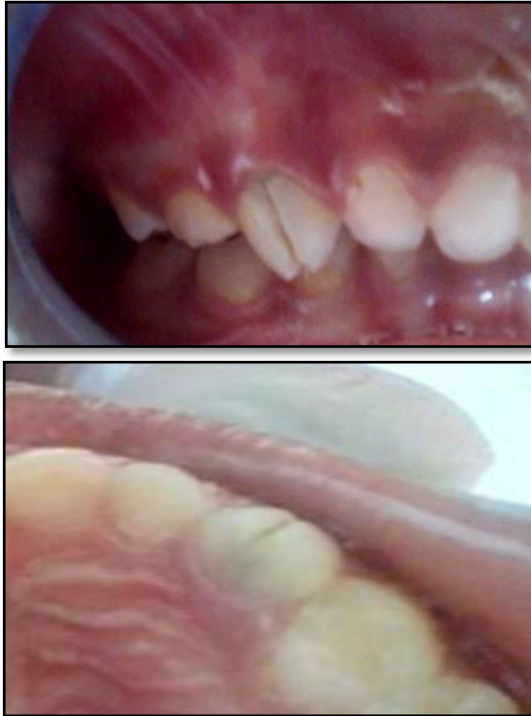

Figure 2:- Intraoral clinical presentation of the patient

Radiographically, root was seen to be unaffected and did not show any sign of fracture or pathology. Hence, its preservation was thought to be an option for maintaining the space. [Figure 3]

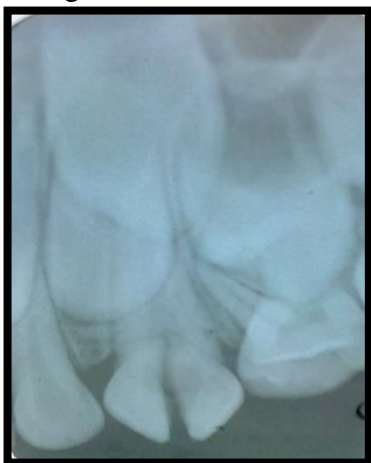

Figure 3:- Radiographic presentation

Histologic evaluation of the extirpated pulp tissue from the root of the affected tooth showed pulp necrosis. [Figure 4]

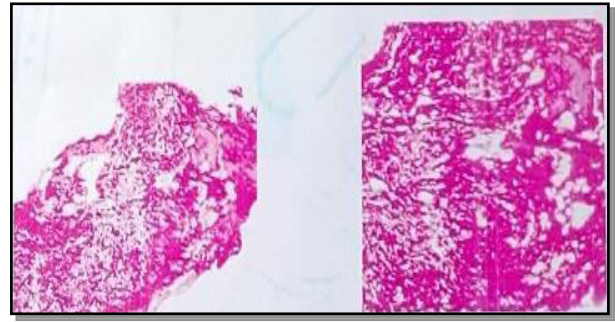


Figure 4:- Histologic evaluation of extirpated pulp tissue

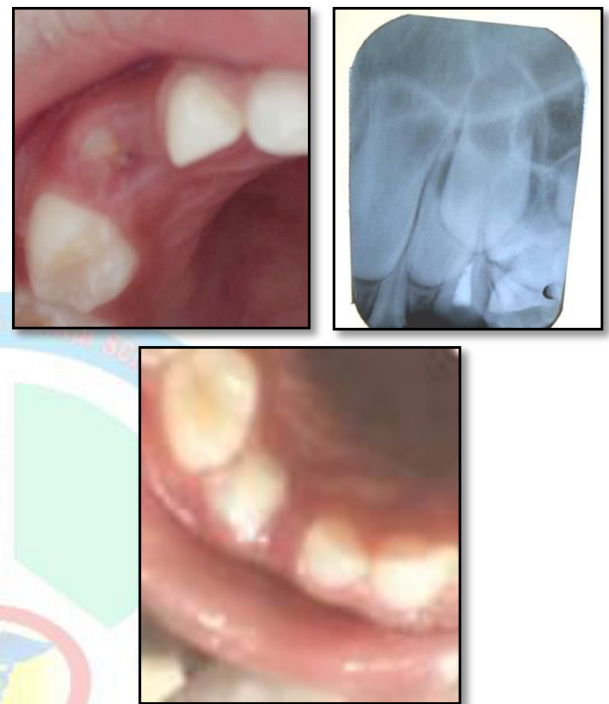

Figure 5:- Post-extraction of crown segments, completed pulpectomy treatment, GIC button placement

After attaining the consent from the parent, the fractured crown segments were extracted under local anaesthesia. Next, endodontic treatment i.e. pulpectomy was done followed by placement of Glass ionomer cement button. [Figure 5] A composite tooth (X-A2 shade of SolarX) was used as a pontic as a replacement of the crown and was fabricated using indirect technique. [Figure 6] Composite tooth pontic was attached to the adjacent natural using polyethylene fibre which a type of a fibre reinforced composite material (Ribbond, bondable reinforcement ribbon). Acid etching of the adjacent teeth was done with 37% of phosphoric acid, bonding agent was applied which was cured for 20 seconds. The fibre was

measured, cut and made into a fan shaped end to increase the surface area for adhesion. It was adhered to the adjacent natural teeth using composite on the palatal surface. The occlusion was checked to ensure complete comfort for the patient. [Figure 7]



Figure 6:- Fabrication of composite tooth using indirect method

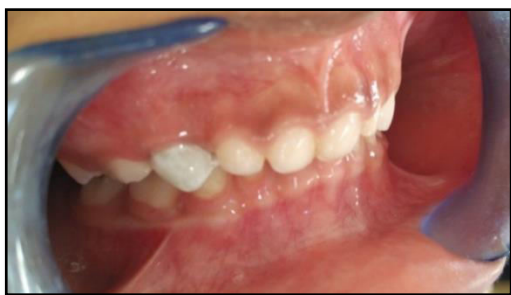

Figure 7:- After final placement of composite tooth pontic using polyethylene fibre

RESULTS

The tooth served the purpose successfully for the patient. The technique showed satisfactory results after 3 months follow up.

DISCUSSION

Accidents within and around the home have been reported as being the major source of injury to the primary dentition.¹ In 3–5-year-olds attending kindergarten 18.0% of children showed traumatic injuries.² A traumatically affected deciduous anterior tooth could be done using different therapeutic options. Nowadays, aesthetics plays a vital role for the satisfaction of the patients.

In the reported case, the root of the affected tooth was preserved till it's successor tooth erupts. Pulpectomy in the root was done using Metapex as a root canal filling as it was stated to be an ideal material as stated in the literature.^{3,4} Tooth Replacement can be done

using patient's natural tooth⁵, an acrylic tooth, or composite resin as a pontic. In this case, good esthetics, unavailability of natural tooth and the possibility of direct chair-side application dictated the use of the composite resin tooth as the pontic as it showed a functional survival rate of 95% after a follow-up period of 4.3 years.^{6,7} The composite pontic was attached using fibre reinforced composite resin. This fibre reinforced composite materials can be Glass fibre, Carbon fibres, Kevlar fibres, Vectran fibres or Polyethylene fibres. Polyethylene fibre was used in this case because it is bondable, ultrahigh-strength with a lock stitch feature. It adapts to the contours of the teeth and dental arch as it does not have memory, bonds to any composite system, easily manageable and most importantly aesthetic.⁸ The patient will be recalled every 3 months for evaluation of growth to avoid any hindrances in growth of the jaw by changing the fibre attachment.

CONCLUSION

The technique presented in this article suggests a successful treatment option for the replacement of a missing deciduous anterior tooth. This restores aesthetics, function, more comfortable compared to a removable appliance. It is a conservative and non-invasive approach. Hence, use of composite pontic in primary dentition along-with polyethylene fibre is a good option.⁹⁻¹²

REFERENCES

- 1) Bastone EB, Freer TJ, McNamara JR, Epidemiology of dental trauma: A review of the literature, Australian Dental Journal 2000; 45:(1):2-9.
- 2) Carvalho, Vinker, Declerck, Malocclusion, dental injuries and dental anomalies in the primary dentition of Belgian children, International Journal of Paediatric Dentistry 1998; 8(2):137-141.
- 3) Trairatvorakul C, Chunlasikawan S. Success of Pulpectomy With Zinc Oxide-Eugenol Vs Calcium Hydroxide/Iodoform Paste in Primary Molars: A Clinical Study. Ped Dent 2008; 30(4):303-9.
- 4) Rifkin A. The root canal treatment of abscessed primary teeth: A three to four year follow-up. J Dent Child 1982; 49: 428-31.
- 5) Goel D, Goel GK. Restoring Esthetics after Anterior Tooth Loss for a Five-Year-Old Child: Natural Tooth Pontic Fiber Reinforced Prosthesis. Case Reports in Dentistry, 2013; 1: 1-3.

- 6) Freilich MA, Meiers JC. Fiber-reinforced composite prostheses. Dent Clin North Am. 2004; 48(2):545-62.
- 7) Jain M, Singla S, Bhushan BAK, Kumar S, Bhushan A. Esthetic rehabilitation of anterior primary teeth using polyethylene fiber with two different approaches, JISPPD 2011 ;29(4): 326:32.
- 8) Maden EA, Altun C, Use of Polyethylene Fiber (Ribbon) in Pediatric Dent, Arch Clin Exp Surg 2012;1: 110-5.
- 9) Shuman IE, Replacement of a tooth with a fiber-reinforced direct bonded restoration, Gen Dent.2000; 48(3):314-8.
- 10) Vallittu PK. Survival rates of resin-bonded, glass fiber reinforced composite fixed partial dentures with a mean follow-up of 42 months: a pilot study. J Prosthet Dent 2004; 91:241-6.
- 11) Chan DC, Giannini M, Goes MF. Provisional anterior tooth replacement using non-impregnated fiber and fiber-reinforced composite resin materials: A clinical report. J Prosthet Dent 2006; 95:344-8.
- 12) Mishra N, Single visit natural tooth pontic bridge using fibre reinforced composite – A clinical report. Clinical Dentistry 2013:23-8.

Source of support: Nil

Conflict of interest: None declared

This work is licensed under CC BY: ***Creative Commons Attribution 3.0 License.***

