

Case Report

TUNNEL PREPARATION: MANAGEMENT OF CLASS III FURCATION INVOLVING MANDIBULAR MOLARS

Ujas P. Shah, Meha Shah, Tanya Shukla, Sarath Chandran

Department of Periodontics and Implantology, Manubhai Patel Dental College, Vadodara, Gujarat, India.

Abstract:

The treatment of furcation involvement is a great challenge to the general periodontists. Tunneling may be a treatment alternative for class II or III furcation involvements in mandibular molars. It is a conservative treatment alternative that allows a great condition for oral hygiene maintenance by the patient. Thus, the aim of this case report was to describe a conservative and therapeutic treatment modality for the horizontal defect of periodontal tissues in the furcal area with buccal-lingual extension (class III furcation involvement). A patient with satisfactory oral hygiene, presented with class III furcation involvement in the right 1st mandibular molar. The final result of the treatment with tunneled crown was favorable and predictable due to adequate hygiene maintenance to avoid plaque accumulation and occurrence of root caries. A multidisciplinary approach is essential to achieve a correct treatment plan including surgical-periodontal procedures integrated to the prosthetic rehabilitation.

Key words: Furcation involvement, Tunnel preparation, Furcation, Periodontal disease.

Corresponding Author: Ujas P. Shah, Department of Periodontics and Implantology, Manubhai Patel Dental College, Vadodara, Gujarat, India.

This article may be cited as: Shah UP, Shah M, Shukla T, Chandran S. Tunnel Preparation: Management of Class III Furcation involving Mandibular Molars. J Adv Med Dent Scie Res 2015;3(1):152-155.

INTRODUCTION

The primary etiology of periodontal diseases is the presence and maturation of a bacterial biofilm eliciting a host response.^[1] Molar teeth with furcation involvement are the most common teeth to be lost. Successful treatment to retain furcation-involved teeth remains one of the most difficult treatments in overall periodontal therapy. Methods for the treatment of furcation-involved molars have shown varying degrees of success.^[2] Advanced furcation lesions can be treated by “tunneling”, i.e. the intentional creation of a class III furcation with its entrance accessible for oral hygiene maintenance. Care must be taken that the space obtained under the roof of the furcation will allow proper plaque removal.^[3]

CASE REPORT

A 58 yr old patient with satisfactory oral hygiene, presented with class III furcation

involvement in the right 1st mandibular molar reported in department of periodontics, Manubhai Patel Dental College, Vadoadara. He was referred from endodontic department after endodontic treatment for further periodontal treatment as it was endo- perio lesion. According to clinical [figure 1] and radiographic examination [figure 2], horizontal bone loss in the interradicular area and presence of divergent roots were observed.

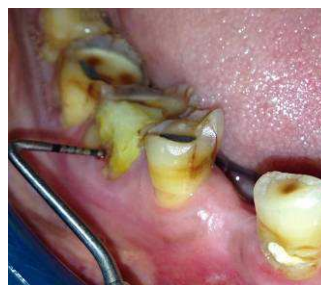

Figure 1: Clinical presentation of 46 with horizontal probing depth 9 mm.

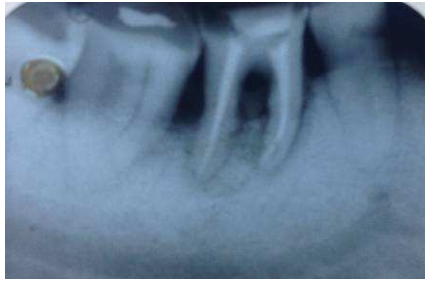


Figure 2: Intraoral periapical radiograph of 44 showing root canal treated tooth and presence of divergent roots.

Tunneling procedure was planned for the treatment of furcation involvement under local anesthesia (2% lignocaine hydrochloride and 1:80,000 adrenaline). A full mucoperiosteal flap was raised with help of sulcular incisions without any vertical incision to expose the furcation [Figure 3]

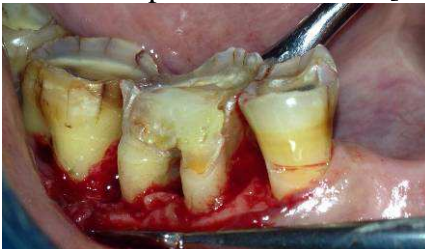


Figure 3: Shows full thickness mucoperiosteal flap was opened and osteoplasty done in furcation area

Complete debridement of granulation tissue and scaling and root planning was done. Interradicular osteotomy was done with round bur and tunnel was prepared and then the flap was repositioned on the alveolar crest and 5-0 resorbable vicryl sutures were given [Figure 4].

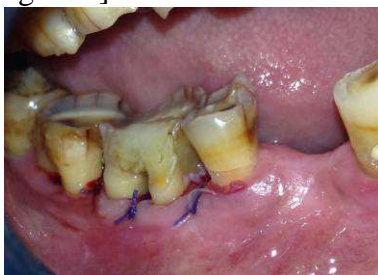

Figure 4: Shows mucoperiosteal flap was placed at tooth -bone junction and 5-0 resorbable vicryl suture placed.

Antibiotics and analgesics were prescribed to prevent post-operative infection and pain. Sutures were removed after 1 week. Patient was educated for mechanical and chemical

plaque control (60 second rinses with 2% chlorhexidine) and patient was given interproximal brush to maintain furcation area [Figure 5 and 6].

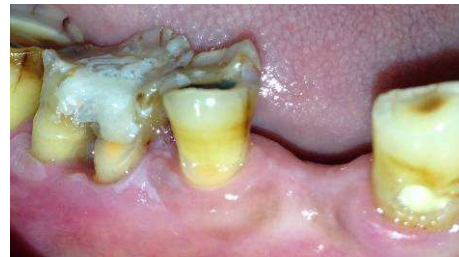

Figure 5: Clinical aspect showing uneventful healing after 1 month

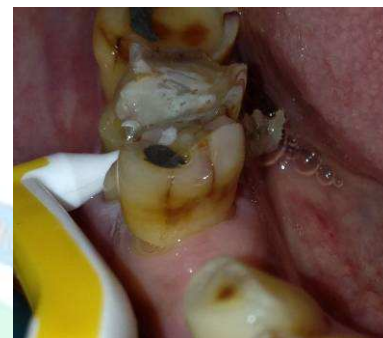

Figure 6: Shows interproximal brush going through the furcation for patient maintenance

Ni Cr Crown was placed after 1 month of surgery. Patient is on regular follow-up at 6 months post-operative. [Figure 7 and 8].

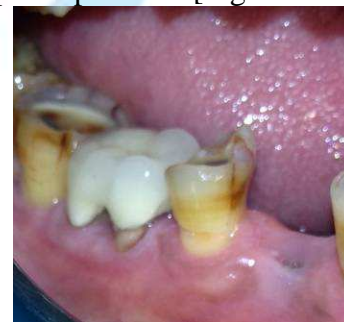

Figure 7: Clinical aspect of tunnelled crown at 6 months

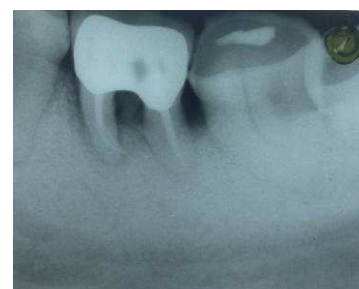

Figure 8: Intraoral periapical radiograph of 44 tunnelled crown after 6 months

DISCUSSION

According to Hamp *et al.*^[2] the furcation involvements can be classified according to the magnitude of interradicular area involvement as shown in table no 1.

Langer^[7] stated that the treatment choice is difficult since many variables should be consider for treatment of furcation involvements like proximity and parallelism between roots, narrow furcation that makes difficult to take periodontal sutures, apical

Table 1: Treatment alternatives for teeth with different grades of furcation involvement

Furcation involvement	Description	Treatment alternatives
Class I	Early involvement with horizontal loss of supporting periodontal tissues not exceeding 1/3 of the tooth width – the probe does not penetrate more than 2mm in the furcation.	Scaling and root planing, furcation plasty
Class II	Moderate involvement with horizontal loss of supporting periodontal tissues achieving more than 1/3 of tooth width but no encompassing the total furcation width – the probe penetrates more than 2mm without transpierce to the opposed side of the furcation.	Furcation plasty Tunneling Root resection Guided tissue regeneration Exodontia
Class III	Buccal-lingual involvement with complete horizontal loss of supporting periodontal tissues – the probe transpierces the both sides of the furcation.	Tunneling Root resection Exodontia

The tunnel preparation of multi-rooted teeth is a conservative approach in the treatment of class II and III furcation involvement. Tunneling has high success rates (85.7 to 93.3 from 1 to 8 years).^[4]

This treatment modality is mostly indicated for mandibular molars with advanced class II or class III furcation involvements.

The horizontal tissue defect depth determines the healing potential at furcation-involved sites. If the horizontal tissue defect did not exceed 3 mm, periodontal health could be established at furcation-involved sites merely by means of scaling, root planing and, if required furcation plasty.^[5] The tunneling technique shows some advantages in comparison to other alternative furcation treatment like, direct access to furcation area for the plaque control by the patient, cost effectiveness, and recovery of alveolar bone crest after surgery with minimum trauma to patient. Other factors to be taken in consideration for tunnel preparations are root anatomy, grade of furcation involvement, extent of periodontal disease, bone loss in furcation lateral and apical to the defect and the tooth mobility.^[6]

fusing and furcation located in the medium or apical third.

Limitation of doing tunnel preparation is that it might provoke a pulp reaction as it exposes a large root surface area relative to the root length and occurrence of root caries, periodontal disease or inadequate plaque control without regular professional follow up.^[8] But in our case, as the tooth was already endodontically treated, the chances of root caries is minimized.

After tunneling procedure being performed, patient must follow the oral hygiene instructions. According to Helldel *et al.*^[9] the hygiene should include mechanical cleaning with interproximal brush in the tunnel area, mouthwash with 0.1 % digluconate of chlorhexidine during 4-6 weeks after surgery, daily mouthwash with 0.025% sodium fluoride, and tooth brushing with fluoride containing dentifrices using appropriate devices for cleaning (interproximal brush) associated with chlorhexidine and also suggested radiographic examination during follow up to evaluate possible root or incipient caries which may cause treatment failure.

A very limited number of studies have been performed on tunnel preparation, with differing results. However, the study by Helldel *et al* ^[9] who enrolled a considerable number of patients, demonstrated promising results. Tunneled teeth appear to be at higher risk for the development of caries. But it can be avoided with proper hygiene maintenance by the patient and regular maintenance recall. Therefore, the tunnel preparation should be considered a valid treatment modality for advance furcation involvements.

CONCLUSION:

The success of treatment for furcation involvement depends upon accurate diagnosis which is based on clinical and radiographic examination. As well as a multidisciplinary approach is necessary for correct treatment planning and its longevity and patient education for oral hygiene maintenance to avoid caries in the treated areas. As tunnel preparation has good successful rate, it may be considered as one of the alternative treatment for advance furcation involvements.

REFERENCES:

1. Socransky SS, Haffajee AD. Periodontal microbial ecology. *Periodontol* 2000. 2005;38:135-87.
2. Hamp SE, Nyman S, Lindhe J. Periodontal treatment of multirooted teeth. Results after 5 years. *J Clin Periodontol* 1975;2:126-135.
3. Bower RC. Furcation morphology relative to periodontal treatment. Furcation root surface anatomy. *J Periodontol* 1979;50:366-74.
4. Vandersall DC, Detamore RJ. The mandibular molar class III furcation invasion: a review of treatment options and a case report of tunneling. *J Am Dent Assoc.* 2002;133:55-60.
5. Hamp SE, Nyman S, Lindhe J. Periodontal treatment of multirooted teeth. Results after 5 years. *J Clin Periodontol* 1975;2:126-135.
6. Huynh-Ba G, Kuonen P, Hofer D, Schmid J, Lang NP, Salvi GE. The effect of periodontal therapy on the survival rate and incidence of complications of multirooted teeth with furcation involvement after an observation period of at least 5 years: a systematic review. *J Clin Periodontol* 2009;36:164-176.
7. Langer B. Root resections revisited. *Int J Periodontics Restorative Dent.* 1996;16: 200-1.
8. Kalkwarf KL, Reinhardt RA. The furcation problems. Current controversies and future directions. *Dent Clin North Am* 1988;32:243-266.
9. Hellden LB, Elliot A, Steffensen B, Steffensen JE. The prognosis of tunnel preparation in treatment of class III furcations. A follow-up study. *J Periodontol* 1989;60:182-187.

Source of support: Nil

Conflict of interest: None declared