

Case Report

Management of Large Maxillary Defect- A Simple & Economic Approach for Patient's Comfort

Abdul Habeeb Bin Mohsin¹, Faisal Taiyebali Zardi²

¹Department of Prosthodontics, MNR Dental College and Hospital, Sangareddy.

²Department of Oral Medicine & Radiology, Sri Sai College of Dental Surgery, Vikarabad.

Abstract:

Corresponding Author:

Dr. Faisal Taiyebali Zardi

8-1-364/36 Deluxe Colony,

Tolichowki,

Hyderabad,

India,

PIN- 500008

E-mail: faisal320@yahoo.com

Immediate temporary or permanent rehabilitation of maxillary defect can be achieved by the fabrication of obturator prosthesis. Retentive components such as clasps can be used with conventional obturator for the treatment of most of the maxillary defects. The primary goal of prosthetic rehabilitation is closure of the defect. Separation of the oral cavity from the sino-nasal cavities prevents hyper-nasal speech and liquid leakage into the nasal cavity. This case report describes the prosthetic rehabilitation of maxillary defect with an obturator prosthesis using clasps as retention components and tissue surface relining by using soft liner which provided a great degree of comfort to the patient. Goal of this case report is to outline basics of treatment planning of hard and soft palate defect keeping in consideration the patient's comfort, less cumbersome clinical & lab procedures, economic and faster delivery time.

Received: 11-07-2014

Accepted: 06-08-2014

Key-words: Rehabilitative team, Maxillary defect, Maxillofacial impression, Obturator.

This article may be cited as: Habeeb Bin Mohsin, Zardi FT. Management of Large Maxillary Defect- A Simple & Economic Approach for Patient's Comfort. J Adv Med Dent Scie Res 2014;2(3):155-160.

Introduction:

Immediate temporary or permanent rehabilitation of maxillary defect can be achieved by the fabrication of obturator prosthesis. Retentive components such as clasps can be used with conventional obturator for the treatment of most of the maxillary defects.¹ Sometimes because of the general health of the patient and other medical conditions, appropriate surgical reconstruction of maxillectomy defects is not possible. In maxillectomy cases surgical reconstruction of defect with help of soft tissue flap cause local infections and unpleasant odors due to tendency of mucous accumulation on the nasal side of the flap and also it loses the ability to keep

a routine check on defect for recurrence of disease.²

Moreover, the removable prosthesis allows easy examination of surgical site which helps in timely detection of tumor recurrence and assessment of adjacent area. Good results can be achieved with thorough assessment of the defect site, simple designing and proper position of retentive components.^{3,4} The primary goal of prosthetic rehabilitation is closure of the defect. Separation of the oral cavity from the sino-nasal cavities prevents hyper-nasal speech and liquid leakage into the nasal cavity. Support, retention and stability are the basic principles must be applied in

designing the prosthesis. To minimize the stress to the structures of the mouth, basic principles must be followed.^{3,4} Directly or indirectly residual ridges, remaining natural teeth, hard palate, remaining soft palate and endosseous implants together or individually will contribute to support, retention and stability. All the supporting structures and possibilities need to be considered before prosthetic treatment is undertaken.⁵ Larger prosthesis create more weight which may impact the retention of prosthesis.⁶ In determining the prognosis potential for indirect retention, retentive undercuts and location of fulcrum line will be the important factors to be considered.⁷ During swallowing, speaking & breathing soft palate works in coordination with the pharyngeal walls and other surrounding muscles.⁸ Compromised Physiological functions deglutition, speech & respiration causes physical and psychosocial concerns for the patients.⁹ The main objective of prosthetic treatment is to prevent food and fluid regurgitation and to improve speech. Goal of this case report is to outline basics of treatment planning of hard and soft palate defect keeping in consideration the patient's comfort, less cumbersome clinical & lab procedures, economic and faster delivery time.

Case Report:

A 64 year old male patient reported to the department of Prosthodontics with the partial hard & soft palate defect involving midline. Patient gives history of Palatal surgery 2 years back due to tumor since then patient is unable to swallow properly, patient's speech is altered and exhibited regurgitation problems. An obturator prosthesis relined by soft liner retained by wire clasps is been fabricated.

Procedure: (Figures 1-12)

Maxillary defect is carefully visualized and examined. Remaining soft tissue of the defect area is found to be sensitive when the assessment of the borders is done. Hence the defect area is desensitized with the help of surface anesthetic spray. Material of

choice for impression making in this case is Alginate for its property of elasticity & ease of retrieval from the undercut area.¹⁰ Perforated stainless steel impression tray is used, tray extension is done with the green stick compound for the basal support of the impression material. Retention holes are created in the tray extension area for the impression material to flow get interlocked into it and material is retained on the tray after recording the defect. Alginate is mixed with recommended water/powder ratio, loaded onto the tray, posterior most area is seated first focusing on the defect which is recorded.

Cast obtained by pouring type III dental stone. Cast trimming is done all around. Border extensions as seen in patient's mouth is transferred on the obtained stone cast. Custom tray fabrication done, tray handle is made with required dimensions for the purpose of checking the borders and soft liner extensions before final insertion. Custom tray is trimmed according to the extensions marked & borders are rounded and smooth. Tray border marked & lined with eosin pencil is seated in patient's mouth to note the muscle activity, patient is asked to perform valsalva maneuver and swallowing action.⁸ Patient complained of tray impingement and tissue surface touching the soft tissue causing discomfort hence fine corrections are done accordingly. Two simple stainless steel wire c-clasps are made bilaterally for the retention of the prosthesis. First clasp adapted around Maxillary right canine & Second on Maxillary left second premolar considering them to be the sound natural teeth available for the purpose.¹ Tissue surface of the prosthesis covering defect area is visualized, 2mm of thickness is trimmed off to accommodate the soft liner.

At this stage the prosthesis is lined with soft liner and retentive clasps are incorporated in the prosthesis. Prosthesis is seated in the patient's mouth to check for the final adjustments. Patient seated in upright position and asked to perform all necessary intra oral movements & functions. In the

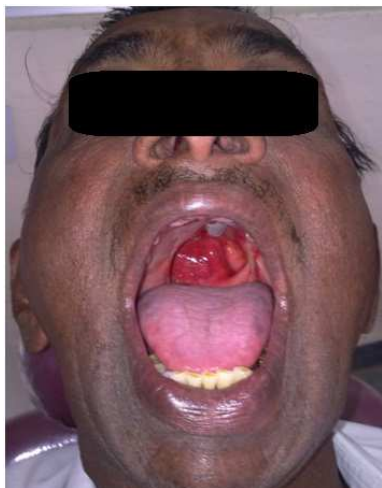

Figure 1: Frontal view - visualizing the defect

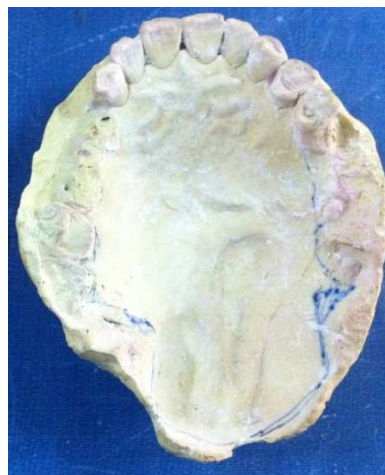

Figure 4: Cast obtained using dental stone

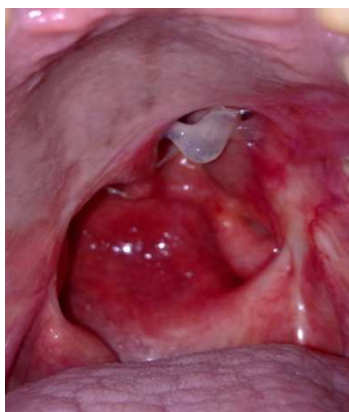


Figure 2: Maxillary defect

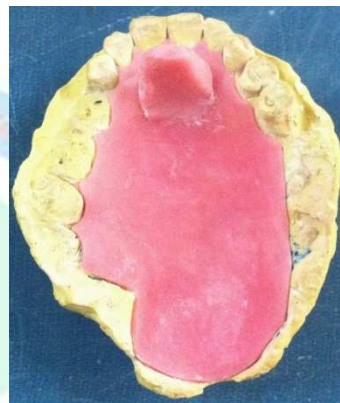

Figure 5: Custom Tray with Handle Fabricated



Figure 3: Alginate Impression made

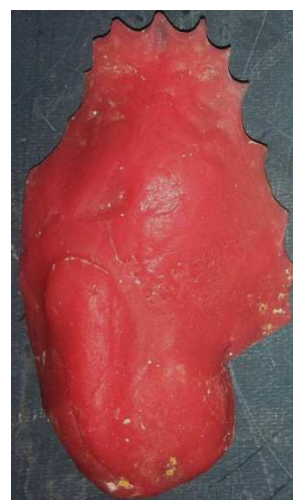

Figure 6: Tissue side of custom tray

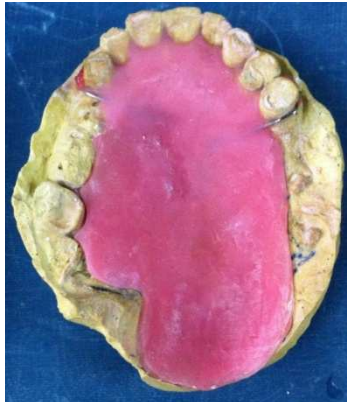

Figure 7: Retentive components incorporated in the Acrylic Plate

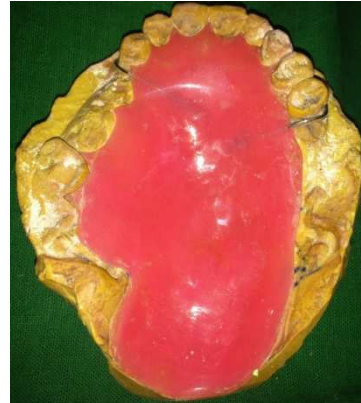

Figure 10: Prosthesis with Retentive components and Soft liner



Figure 8: Soft liner used for lining the defect area

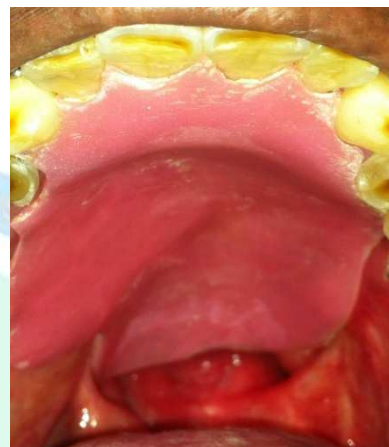

Figure 11: Prosthesis Tryin Done

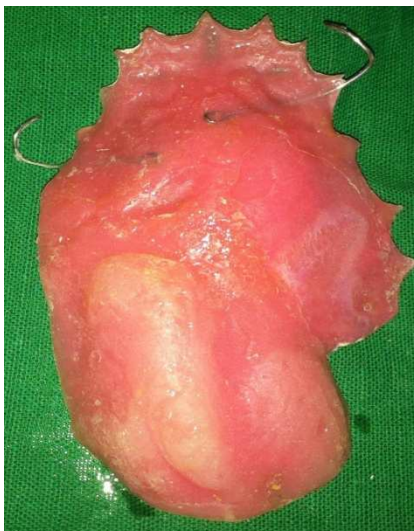

Figure 9: Tissue side of Prosthesis with Soft liner

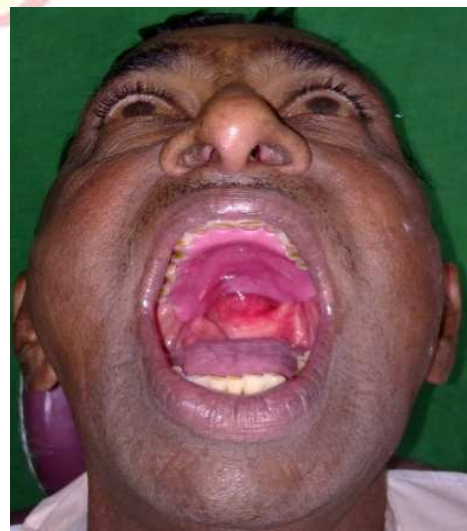

Figure 12: Obturator Prosthesis Insertion done

defect area during swallowing patient felt discomfort as tissue side of the prosthesis was touching & interfering with the normal muscle movement. Hence 0.5 mm of relief given by removal of soft liner material provided much comfort to the patient. Complete polishing and smoothening of the prosthesis was done and Prosthesis insertion done. Patient recalled for a review after one week, there were some small corrections done as per the patient's comfort and the patient was satisfied.

Discussion:

Alginate is the material of choice in maxillofacial impressions as it comes out as one piece after it sets in the defect area. Impression is accepted when the defect borders, favourable undercuts & supporting structures are recorded properly. Alginate should be poured immediately to avoid shrinkage.¹⁰ Elastomeric impression materials are contraindicated in some cases because of its rigidity and hydrophobic nature.

Over extensions posteriorly to be checked and trimmed according to the muscle activity.⁸ It is important for the retention of the tray as the loose tissue present posteriorly may dislodge the prosthesis and may be a reason for poor retention and causes discomfort to the patient during normal function such as swallowing. At the same time without interfering normal surrounding muscle activity, seal is been kept intact by keeping the prosthesis in contact with the surrounding soft tissue structure to prevent fluids and food from leaking into the nasal/antral area.⁵ In this case there is no additional retention taken from the defect undercut as the tissue was sensitive and we did not want to cause discomfort to the patient. Hence the local anesthetic agents were used during impression making to avoid discomfort to the patient.

Necessary steps carried out to reduce cytotoxicity of acrylic resin.¹¹ Post insertion instructions given to the patient to avoid oral infections.¹² Regular checkups required to check for progressive tissue changes.

Check up recommended for every 3-4 months.

Conclusion:

Good communication is necessary between the surgical team and rehabilitative team for the desired defect which may ease the prosthetic treatment and may allow the prosthetist to apply all the basic principles in prosthesis design. Team work of Surgical Oncologist, Maxillofacial Surgeon, Prosthodontist, Speech Pathologist and Nutritionist can best rehabilitate the Patients with Maxillary defect.

References:

1. King GE, Martin JW. Cast circumferential and wire clasps for obturator retention. J Prosthet Dent 1983;49(6):799-802.
2. Beumer J, Curtis TA, Marunick MT: Maxillofacial Rehabilitation Prosthodontic and Surgical Considerations, 2nd edition. St. Louis, MO, Ishiyaku Euroamerica Inc, 1996, pp. 225-247.
3. Aramany MA. Basic principles of obturator design for partially edentulous patients: Part I: classification. J Prosthet Dent 1978;40:554-557.
4. Aramany MA. Basic principles of obturator design for partially edentulous patients: Part II: design principles. J Prosthet Dent 1978;40:656-662.
5. Brown KE: Peripheral consideration in improving obturator retention. J Prosthet Dent 1968;20:176-181.
6. Wu YL, Schaaf NG: Comparison of weight reduction in different designs of solid and hollow obturator prostheses. J Prosthet Dent 1989;62:214-217.
7. Schwartzman B, Caputo AA, Beumer J: Gravity-induced stresses by an obturator prosthesis. J Prosthet Dent 1990;64:466-468.
8. Matsuyama M, Tsukiyama Y, Koyano K: Objective clinical assessment of change in swallowing ability of maxillectomy patients when wearing obturator prostheses. Int J Prosthodont 2005;18(6):475-479.

9. Kornblith AB, et al. Quality of life of maxillectomy patients using an obturator prosthesis. *Head Neck* 1996;18(4):323-334.
10. V Vidyashree Nandini, K Vijay Venkatesh, K Chandrasekharan Nair: Alginate impressions: A practical perspective. *J Conserv Dent* 2008;11(1):37-41.
11. Siqueira Goncalves T, et al. Cytotoxicity of two autopolymerized acrylic resins used in Orthodontics. *The Angle Orthodontist* 2008;78(5):926-930.
12. Pavan S, et al: Effect of disinfection treatments on the hardness of soft denture liner materials. *J Prosthodont* 2007;16(2):101-106.



Source of support: Nil

Conflict of interest: None declared