

## Original Research

### Histopathological assessment hepatobiliary cystic lesions in tertiary care centre

Dr. Shefali M L Gupta,

Associate Professor, Department of Pathology, Venkateshwara Institute of Medical Sciences, Gajraula, Uttar Pradesh, India

#### ABSTRACT:

**Background:** The present study was conducted to assess hepatobiliary cystic lesions in tertiary care centre. **Materials & Methods:** 148 hepatobiliary cystic lesions were hematoxylin and eosin stained slides, silver reticulin, Masson's trichrome, periodic acid Schiff (PAS), and Voehrhoff Van Gieson stains. **Results:** Age group 11-20 years had 5, 21-30 years had 14, 31-40 years had 45, 41-50 years had 36, 51-60 years had 28 and >60 years had 20 cases. Most common hepatobiliary cystic lesions was choledochal cyst in 72, hydatid cyst in 51, simple cyst liver in 8, CHF in 2, biliary cystadenoma in 6, liver abscess in 5 and cavernous hemangioma in 4 cases. The difference was significant ( $P < 0.05$ ). **Conclusion:** Most common hepatobiliary cystic lesions was choledochal cyst, hydatid cyst and simple cyst liver.

**Key words:** Hepatobiliary cystic lesions, Hydatid cyst, hematoxylin and eosin.

Received: 12 July, 2019

Accepted: 14 August, 2019

**Corresponding author:** Dr. Shefali M L Gupta, Associate Professor, Department of Pathology, Venkateshwara Institute of Medical Sciences, Gajraula, Uttar Pradesh, India

**This article may be cited as:** Gupta SM. Histopathological assessment hepatobiliary cystic lesions in tertiary care centre. J Adv Med Dent Scie Res 2019;7(9):214-217.

#### INTRODUCTION

Cysts of the hepatobiliary tree are a group of heterogeneous lesions with regard to the pathogenesis, clinical presentation, diagnostic findings, and therapeutic management. Most of them are asymptomatic and incidentally detected on abdominal imaging such as ultrasonography (USG), computed tomography (CT), and magnetic resonance imaging (MRI).<sup>1</sup> A few of them, however, may be symptomatic, and rarely associated with serious morbidity and mortality. The latter, are the larger cysts, which cause complications such as spontaneous hemorrhage rupture into the peritoneal cavity or bile duct, infection and compression of adjacent biliary tree.<sup>2</sup> Hepatic lesions with a multilocular cystic appearance are frequently encountered in routine radiologic practices.<sup>3</sup> The spectrum of the hepatobiliary cystic lesions might vary in different geographical regions, due to differences in etiological factors in different climatic conditions. This imaging pattern covers a wide spectrum of common and uncommon entities.<sup>4</sup> A cystic lesion is a well-defined lesion with predominant near-water attenuation (0–30

HU) or signal intensity that exhibits negligible enhancement at dynamic imaging; the attenuation or signal intensity can be slightly different from that of pure water because of the diversity in fluid composition. The internal septa are defined as the partitions or membranes that divide the lesion into multiple compartments.<sup>5</sup> Septa may vary in thickness, uniformity, extent of enhancement, and mural nodularity. The present study was conducted to assess hepatobiliary cystic lesions in tertiary care centre.

#### MATERIALS & METHODS

The present study was conducted in the department of general pathology. It comprised of 148 hepatobiliary cystic lesions obtained from surgery department. All histopathological diagnoses established based on observation obtained by two histopathologists. Hematoxylin and eosin stained slides, silver reticulin, Masson's trichrome, periodic acid Schiff (PAS), and Voehrhoff Van Gieson stains were performed and analyzed as per applicability. Results thus obtained were subjected to statistical analysis. P value less than 0.05 was considered significant.

## RESULTS

**Table I Distribution of samples**

Total- 148		
Gender	Male	Female
Number	90	58

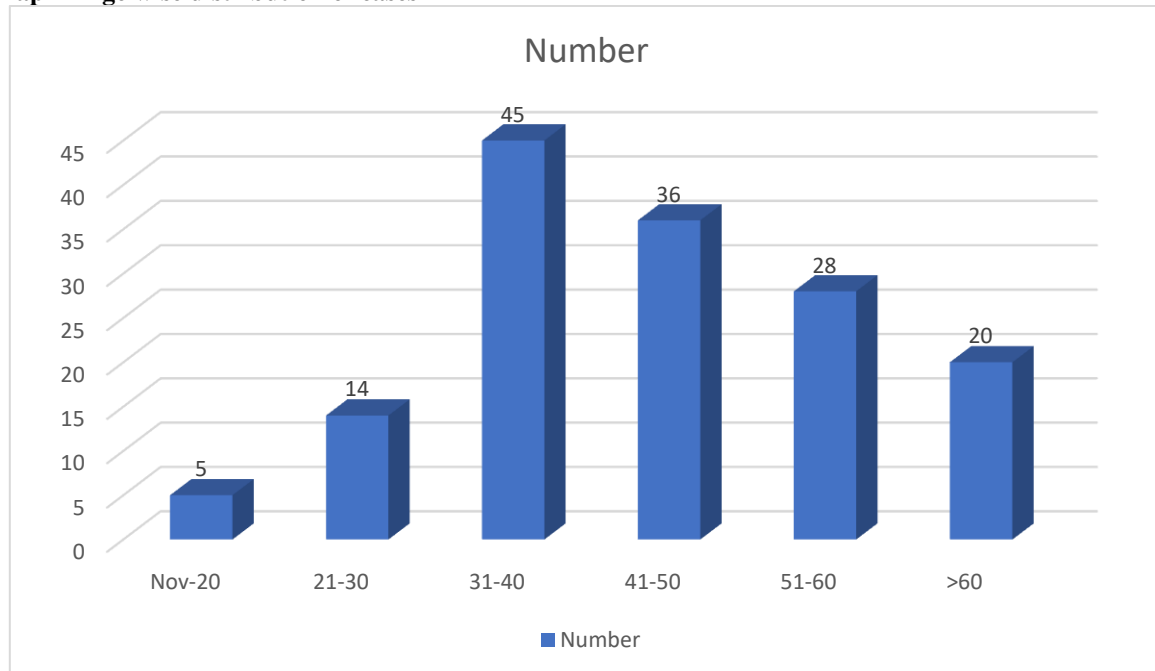
Table I shows that out of 148 samples, 90 were of males and 58 were of females.

**Table II Age wise distribution of cases**

Age group (Years)	Number	P value
11-20	5	0.015
21-30	14	
31-40	45	
41-50	36	
51-60	28	
>60	20	

Table II, graph I shows that age group 11-20 years had 5, 21-30 years had 14, 31-40 years had 45, 41-50 years had 36, 51-60 years had 28 and >60 years had 20 cases.

**Graph I Age wise distribution of cases**

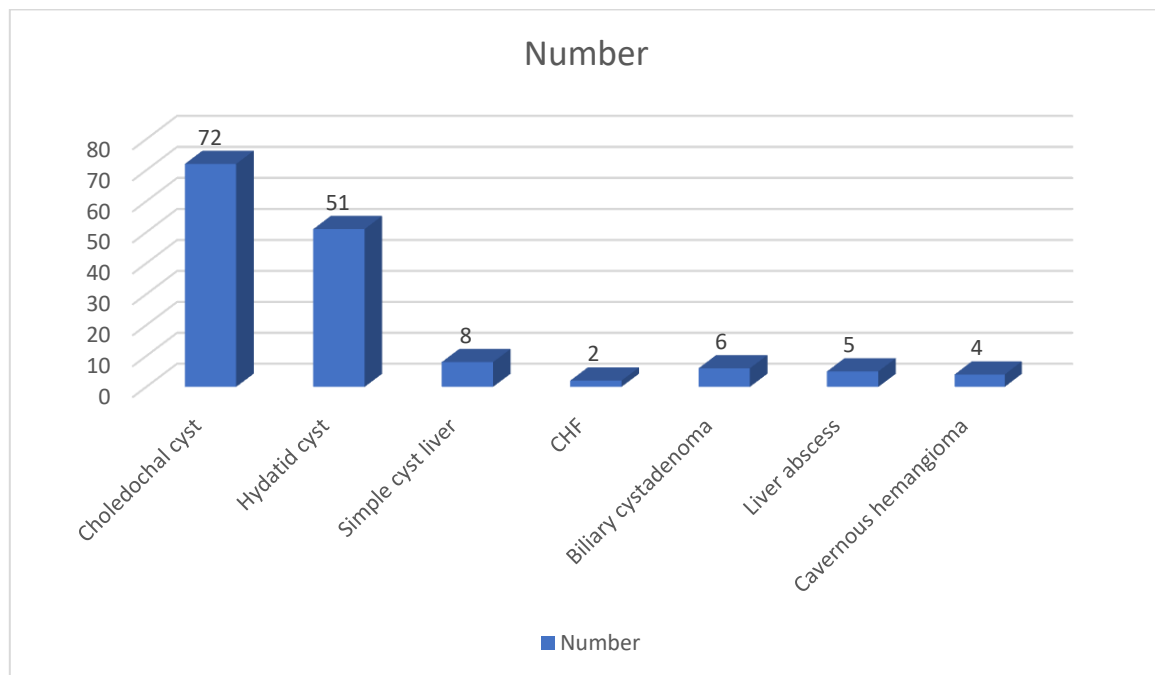


**Table III Assessment of hepatobiliary cystic lesions**

Hepatobiliary cystic lesions	Number	P value
Choledochal cyst	72	0.01
Hydatid cyst	51	
Simple cyst liver	8	
CHF	2	
Biliary cystadenoma	6	
Liver abscess	5	
Cavernous hemangioma	4	

Table III, graph II shows that hepatobiliary cystic lesions comprised of choledochal cyst in 72, hydatid cyst in 51, simple cyst liver in 8, CHF in 2, biliary cystadenoma in 6, liver abscess in 5 and cavernous hemangioma in 4 cases. The difference was significant ( $P < 0.05$ ).

**Graph II Assessment of hepatobiliary cystic lesions**



## DISCUSSION

Cystic hepatic lesions are commonly encountered in daily practice. The differential diagnoses range from benign lesions of no clinical significance to malignant and potentially lethal conditions.<sup>6</sup> Many cystic hepatic lesions have classic imaging findings, and the diagnosis can be made with certainty on the basis of imaging alone.<sup>7</sup> In other cases, recognizing key radiologic features in combination with reviewing the clinical data usually allows the correct diagnosis. Cystic hepatic lesions can be divided into developmental, inflammatory, neoplastic, and trauma-related lesions.<sup>8</sup> An incidental simple hepatic cyst is the most commonly encountered pathologic finding. The number and morphology of the lesions and determination of whether there is a solid component are key imaging features that are helpful for approaching the diagnosis of cystic hepatic lesions.<sup>9</sup> The present study was conducted to assess hepatobiliary cystic lesions in tertiary care centre. In present study, out of 148 samples, 90 were of males and 58 were of females. We found that age group 11-20 years had 5, 21-30 years had 14, 31-40 years had 45, 41-50 years had 36, 51-60 years had 28 and >60 years had 20 cases. Das et al<sup>10</sup> found that a total of 312 cases of hepatobiliary cysts were identified, the majority in females. Choledochal cysts (CCs) were the most common type ( $n = 198, 63.5\%$ ), followed by hydatid cysts ( $n = 73, 23.3\%$ ), simple hepatic cysts ( $n = 10, 3.2\%$ ), congenital hepatic fibrosis ( $n = 10, 3.2\%$ ), biliary cystadenomas ( $n = 4, 1.2\%$ ), hepatic mesenchymal hamartomas ( $n = 7, 2.2\%$ ), and cavernous hemangiomas ( $n = 3, 0.9\%$ ). Fibropolycystic liver disease ( $n = 2, 0.6\%$ ), Caroli's disease ( $n = 1, 0.3\%$ ), liver abscess ( $n = 2, 0.6\%$ ),

infantile hemangioendothelioma ( $n = 1, 0.3\%$ ), and biliary cystadenocarcinomas ( $n = 1, 0.3\%$ ) were rare. Lesions noted mostly in 1<sup>st</sup> decade of life were: CCs, fibrocystic liver disease, Caroli's syndrome, cystic mesenchymal hamartoma, and infantile hemangioendotheliomas.

We found that hepatobiliary cystic lesions comprised of choledochal cyst in 72, hydatid cyst in 51, simple cyst liver in 8, CHF in 2, biliary cystadenoma in 6, liver abscess in 5 and cavernous hemangioma in 4 cases. Rubin and Farber<sup>11</sup> reviewed 157 patients with hydatid disease of the liver and found that, hepatomegaly was the most common sign. Other common presentations were pain, nausea, dyspnea, dysphagia, and jaundice. The cysts can be small and usually become symptomatic when they enlarge up to 10–20 cm in size. In cystic echinococcosis, the cyst wall comprises of three layers. The inner germinal layer which is 10–25  $\mu$  in thickness contains nuclei, which give rise to brood capsules attached with short stalks and daughter cysts. Protoscolices with double row of refractile, birefringent acid-fast hooklets of 22–40  $\mu$ , and four round suckers may be seen.

Both USG and CT scan are reliable in the diagnosis and follow-up of the liver abscesses. The distinction between pyogenic and amoebic liver abscess is difficult by imaging studies. The two can be differentiated by amoebic serology. Liver function tests and stool microscopy are non-discriminatory, and positivity rate of bacterial culture in aspirate and blood is only 50%.<sup>12</sup>

The shortcoming of the study is small sample size.

## CONCLUSION

Authors found that most common hepatobiliary cystic lesions was choledochal cyst, hydatid cyst and simple cyst liver. Maximum cases were observed in age group 31-40 years.

## REFERENCES

1. Morgan DE, Lockhart ME, Canon CL, Holcombe MP, Bynon JS. Polycystic liver disease: multimodality imaging for complications and transplant evaluation. *RadioGraphics* 2006;26(6):1655–1668.
2. Buetow PC, Buck JL, Pantongrag-Brown L, et al. Biliary cystadenoma and cystadenocarcinoma: clinical-imaging-pathologic correlations with emphasis on the importance of ovarian stroma. *Radiology* 1995;196(3):805–810.
3. Lam MM, Swanson PE, Upton MP, Yeh MM. Ovarian-type stroma in hepatobiliary cystadenomas and pancreatic mucinous cystic neoplasms: an immunohistochemical study. *Am J Clin Pathol* 2008; 129(2):211–218.
4. Abdul-Al HM, Makhlof HR, Goodman ZD. Expression of estrogen and progesterone receptors and inhibin-alpha in hepatobiliary cystadenoma: an immunohistochemical study. *Virchows Arch* 2007;450 (6):691–697.
5. Korobkin M, Stephens DH, Lee JK, et al. Biliary cystadenoma and cystadenocarcinoma: CT and sonographic findings. *AJR Am J Roentgenol* 1989;153 (3):507–511.
6. Stevens WR, Gulino SP, Batts KP, Stephens DH, Johnson CD. Mosaic pattern of hepatocellular carcinoma: histologic basis for a characteristic CT appearance. *J Comput Assist Tomogr* 1996;20(3): 337–342.
7. Soochan D, Keough V, Wanless I, Molinari M. Intra and extra-hepatic cystadenoma of the biliary duct. Review of literature and radiological and pathological characteristics of a very rare case. *BMJ Case Rep* 2012;2012.
8. Glinkova V, Shevah O, Boaz M, Levine A, Shirin H. Hepatic haemangiomas: Possible association with female sex hormones. *Gut* 2004;53:1352-5.
9. Kerkar N, Norton K, Suchy FJ. The hepatic fibrocystic diseases. *Clin Liver Dis* 2006;10:55-71.
10. Das P, Sharma P, Nakra T, Ghosh S, Yadav R, Gupta B, Khanna G, Madhusudhan K S, Panwar R, Anoop M K, Kilambi R, Singh AN, Dash NR, Pal S, Gupta SD. Spectrum of hepatobiliary cystic lesions: A 7-year experience at a tertiary care referral center in North India and review of literature. *Indian J Pathol Microbiol* 2017;60:487-500.
11. Rubin E, Farber JL. *Pathology*. 1st ed. Philadelphia: J.B. Lippincott Co.; 1988. p. 444-6.
12. Asuquo M, Nwagbara V, Agbor C, Ootobo F, Omotoso A. Giant simple hepatic cyst: A case report and review of relevant literature. *Afr Health Sci* 2015;15:293-8.