

CASE REPORT

Bridge Flap Technique for Root Coverage in Multiple Teeth Recession- Case Series

Preetika Bansal¹, Pardeep Bansal²

¹Associate Professor, Department of Periodontics, ²Professor and Head, Department of Prosthodontics, Dasmesh Institute of Research & Dental Sciences, Talwandi road, Faridkot, Punjab 151203, India

ABSTRACT:

Gingival recession in anterior teeth is of huge concern due to esthetic reasons. Root coverage is being achieved by a variety of mucogingival techniques. The presence of shallow vestibule, inadequate width of attached gingival, aberrant frenum pull may pose a challenge to cover the denuded root surface for which several independent & effective surgical solutions are reported in the literature. This article reports three such cases of gingival recession, which have been treated with bridge flap technique. This technique can be used as a single surgical entity for covering multiple gingival recession defects, increasing depth of vestibule & also solving the problem of abnormal frenum pull, without a second surgical site. The treated cases demonstrated adequate root coverage & increase in width of attached gingival at 6 months follow up

Key words: bridge flap, root coverage, attached gingival, gingival recession, mucogingival surgery, coronally advanced flap

Corresponding author: Dr Preetika M.D.S, Associate Professor, Department of Periodontics, Dasmesh Institute of Research & Dental Sciences, Talwandi road, Faridkot, Punjab 151203, India

This article may be cited as: Bansal P, Bansal P. Bridge Flap Technique for Root Coverage in Multiple Teeth Recession- Case Series. J Adv Med Dent Scie Res 2017;5(11):33-36.

Access this article online	
Quick Response Code 	Website: www.jamdsr.com
	DOI: 10.21276/jamdsr.2017.5.11.08

INTRODUCTION

Gingival recession is the exposure of the root surface by an apical shift in the position of gingiva.^[1] Marginal tissue recession results in dentinal hypersensitivity, esthetic problems and tendency for root caries. Therefore root coverage procedures have become an important part of regenerative periodontal therapy.^[2] Among the various surgical techniques that have been advocated for treating multiple recession complicated with either inadequate width of attached gingival, aberrant frenum pull or shallow vestibule, the bridge flap have shown better root coverage predictability & esthetics. The primary advantage is that it does not require a separate second frenectomy procedure, can be used for covering multiple gingival recessions without a second surgical site. The double lateral bridging technique was proposed by Marggraf.^[3] This technique utilizes the combination of a coronally advanced flap and modified Edlan & Mejchar technique.^[4] This paper report the surgical management of three patients with bridge flap for coverage of denuded root surfaces.

CASE REPORTS

Three patients with the complaints of recession, esthetics and sensitivity in lower anterior teeth were examined. Various clinical parameters were recorded; gingival recession GR (i.e. distance between CEJ & free gingival

margin), probing pocket depth, PPD, width of keratinized gingival using Williams periodontal probe.

The parameters were recorded before & after the surgery. The surgical procedure was explained to the patients & informed consent was obtained.

Clinical examination

Case 1: A 26 year old female patient revealed presence of diastema and Millar class III gingival recession on left lower central incisor (31), lower left lateral incisor (32) & lower right central incisor (41). The recession was 5mm on all the five teeth. The width of keratinized gingival was 2mm on 31, 41, & 3mm on 32. A PPD of 2mm was present on all the 3 teeth (fig 1).

Case 2: A 23 year old female patient revealed presence of diastema and Millar's class 3 gingival recession on left & right lower central incisor (31, 41). The recession was 5mm on 41, and 3mm on 31. Also, a high frenal attachment was present between these 2 teeth. The width of keratinized gingiva was 1 mm on 41 and 2mm on 31. A PPD of 1mm was present on 41 and 2mm on 31 (fig7).

Case 3: A 27 year old male patient revealed presence of class 3 recession on lower left and right central and lateral incisor (31, 32, 41, and 42). The recession was 1mm on 42 and 2mm on 31, 32 41. The width of keratinized

gingival was 4mm on 42, and 3mm on 31, 32, 41. A PPD of 2mm was present on all teeth (fig 9).

Surgical technique

Before the Surgical technique and after the clinical investigations, scaling & root planing (phase 1 therapy) was performed by ultrasonic and hand instruments, and oral hygiene instructions given to the patients'.

The surgical technique included the bridge flap technique as introduced by Marggraf and later on modified by Romanos.^[5]

Under LA, an arc shaped incision or semi lunar incision was given in vestibule at a distance, which was twice the amount of GR+2mm from gingival margin($2 \times \text{GR} + 2\text{mm}$).

This ensures a wide flap which is necessary for sufficient blood supply. A split thickness flap was elevated in

apico-coronal direction and it was connected with the first incision so that the 2 flaps communicated with each other. The entire flap was coronally positioned to cover the denuded root surface (fig 2). Repositioned flap was pressed for 3 min and then sling sutures were placed (fig 3). A periodontal Coe-Pack was placed on operative site (fig 4). Written post-operative instructions were given to the patient and were prescribed analgesics (Ibuprofen 400 mg thrice daily for 3 days), antibiotic (Amoxicillin 250mg every 8 hours for 5 days). 0.2 % chlorohexidine mouth rinse was instructed till 4 weeks after the surgery. Coe-Pack and sutures were removed 10 days after the surgical procedure (fig 5). Patients were instructed to use soft tooth brush for mechanical plaque control. All the patients were recalled for once a week for review for the 1st month and after 3, 6 months.

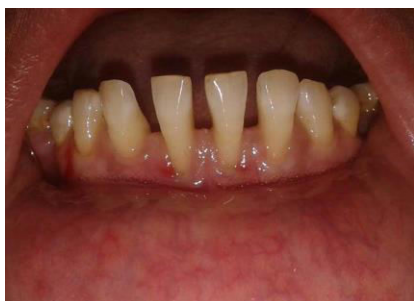

Fig 1

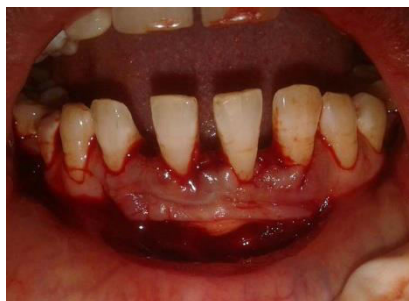

Fig 2

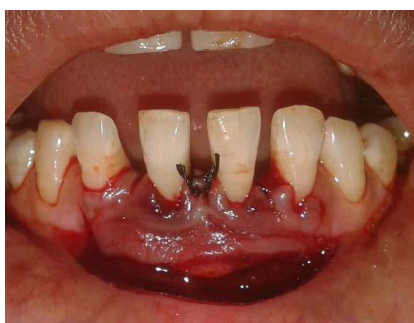

Fig 3

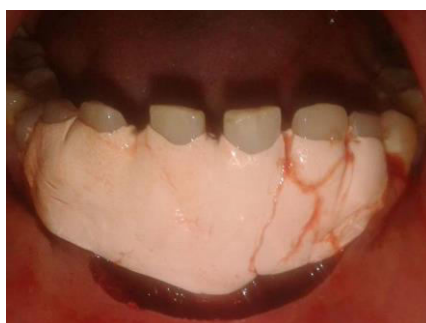

Fig 4

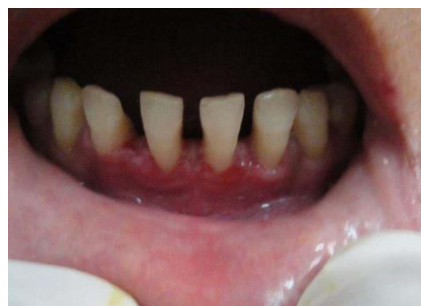


Fig 5

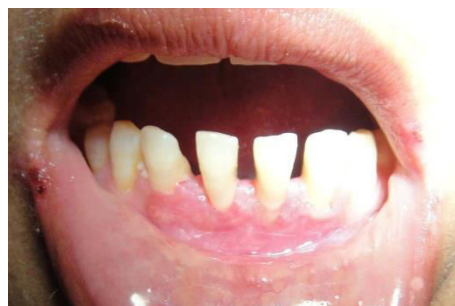

Fig 6

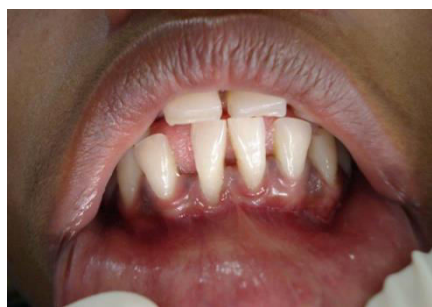

Fig 7

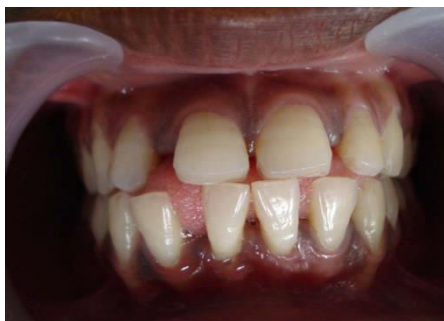

Fig 8

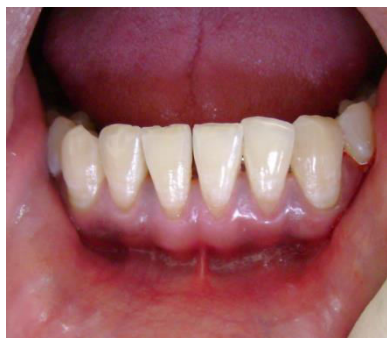

Fig 9

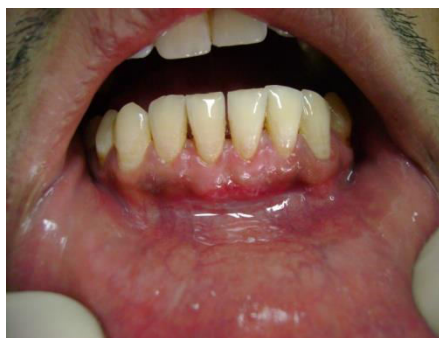

Fig 10

Fig 1: Pre-operative (Case 1); **Fig 2:** Flap coronally displaced; **Fig 3:** Flap sutured coronally; **Fig 4:** Coe-Pack given; **Fig 5:** Post-operative (10 Days); **Fig 6:** Post-operative (3 Months); **Fig 7:** Pre-operative (Case 2); **Fig 8:** Post-operative (3 Months); **Fig 9:** Pre-operative (Case 3); **Fig 10:** Post-operative (3 Months)

RESULTS

Recall examination after a post-operative period of 3 months revealed complete root coverage (fig 6, 8, 10). In case 1, width of attached gingiva increased from 2mm to 7 mm for 31, 41 teeth and 3 to 6mm for 32. PPD of 2mm was present. In case 2, width of attached gingiva increased from 1mm to 6mm for tooth 41 and 2mm to 5mm for 31. PPD of 2mm was present. In case 3, the width of attached gingiva increased from 4mm to 6mm for 42 and 3mm to 5mm for 31, 32 41. PPD of 2mm was present.

DISCUSSION

Root coverage can be performed by various methods to alleviate patients concern regarding unsatisfactory esthetics and root hypersensitivity. However, there still exist an unresolved controversy regarding adequate width of attached gingival and periodontal health maintenance^[6] and the contemporary opinion suggest that the regions with less than attached gingival and thin gingival tissues are at increased risk of GR even if it is possible to maintain the gingival health in the areas with insufficient or absent attached gingiva.^[7] So an evaluation of adequate width of attached gingival in patients with multiple recessions is an important factor before deciding on any procedure for root coverage. Coronally advanced flap is one of the common procedures for root coverage but require adequate width of attached gingiva.^[8] So a variety of techniques to increase the width of attached gingival are performed first. While in double lateral

sliding bridge flap technique, recession coverage in multiple teeth can be done with or without adequate attached gingiva.

In all the cases, the semi-lunar incision raising partial thickness flap in the vestibule combining with the first incision without any vertical incision led to formation of displacement flap that provided better gingival blood supply and also passive adaptation on denuded root surface without apical tension. There was uncomplicated and rapid healing. The presence of diastema between the teeth in cases 1 and 2 did not affect post-operative results. The incidence of re-occurrence of recession is reduced as – by dipping the vestibule, the mucosal flap cannot be influenced by tension from an apical direction and also the frenum pull was relieved by releasing the periosteal fibres.

CONCLUSION

In conclusion, this one step bridge flap technique provided satisfactory results with complete root coverage involving multiple teeth, increasing the width of attached gingival with deepening the shallow vestibule to a desired extent, correcting the aberrant frenum pull, with reduction of dentinal hypersensitivity without any significant complications. It also appears that neither the quality of gingival recession nor the qualities of the supporting tissues are pre-requisites for the success.

REFERENCES:

1. Kassab MM , Cohen RE. The etiology and prevalence of gingival recession. J Am Dent Assoc. 134 (2003) :220-225.
2. Rocuzzo M, Bunino M, Needleman I, Sanz M. Periodontal plastic surgery for treatment of localized gingival recession : a systematic review. J Clin Periodontol. 29(2002) : 178-194.
3. Marggraf E. A direct technique with a double lateral bridging flap for coverage of denuded root surface and gingival extension. Clinical evaluation after 2 years. . J Clin Periodontol. 12(1985) : 69-79.
4. Wade AB. Vestibular deepening by the technique of Edlan and Mejchar. J Periodontal Res. 4 (1969): 300-313.
5. Romanos GE, Bernumoulin JP, Marggraf E . the double lateral bridging flap for coverage of denuded root surface. Longitudinal study and clinical evaluation after 5 to 8 years . J Perodontol. 64 (1993) : 683-688.
6. Remya V , Kumar KK, Sabita S , Arun KB . Free gingival graft in the treatment of class III gingival recession . Indian J Dent Res. 19 (2008):247-252.
7. Popova C ,Kotsilkov K, Doseva V. Mucogingival surgery with free gingival graft (strip technique) for augmentation of the attached gingival tissues : Report of three cases. J IMAB Annl Proc (Scientific Papers). 2 (2007): 25-30.
8. Cheng YF , Chen JW , Lin SJ, Lu HK. Is Coronally positioned flap procedure adjunct with enamel matrix derivative or root conditioning a relevant predicture for achieving root coverage? A systemic review. J Periodontal Res. 42 (2007): 474-485.

Source of support: Nil

Conflict of interest: None declared

This work is licensed under CC BY: *Creative Commons Attribution 3.0 License*.