

REVIEW ARTICLE

MANAGEMENT OF MUTILATED TEETH WITH POST AND CORE: A REVIEW

R. P. Luthra¹, Renu Gupta², Reena Sirohi³, Naresh Kumar³, Savisha Mehta³

¹Professor & Principal, ²Professor & Head, ³Junior resident, Department of Prosthodontics, H.P. Government Dental College & Hospital, Shimla, Himachal Pradesh, India.

ABSTRACT:

Mutilation of teeth due to over-zealous preparation, caries, trauma or secondary spread of decay underneath an existing crown can lead to partial or complete coronal fractures of teeth. With technological advancements in the field of dentistry it is now possible to restore such teeth. This review highlights the role of post and core in the management of badly mutilated teeth.

Keywords: Caries, Coronal fracture, Mutilation.

Corresponding Author: Dr. Reena Sirohi, Room no.401, Department Of Prosthodontics, H. P. Government Dental College & Hospital, Shimla, Himachal Pradesh, India -171001. E-mail address: reena.sirohi@yahoo.in

This article may be cited as: Luthra RP, Gupta R, Sirohi R, Kumar N, Mehta S. Management of mutilated teeth with Post and Core: A Review. J Adv Med Dent Scie Res 2015;3(4):99-101.

INTRODUCTION

Nonvital teeth usually present with unique restorative problems arising because of mutilation by caries, fractures, previous restorative procedures, and endodontic access. Between the various treatment techniques for pulpless teeth quoted in the literature, variations of the dowel-core restoration have been receiving considerable attention.¹

History way backs to more than 200 years stating various methods of restoring pulpless teeth.² Pierre Fauchard (1728) described the use of “tenons” in the roots of teeth to retain prostheses. Claude Mouton in 1746 published his design of a gold crown with a gold post that was to be inserted into the root canal.³

In today's senario, both endodontic and prosthodontic aspects of treatment have advanced significantly with the introduction of new materials and techniques and a substantial body of scientific knowledge is available on which clinical treatment decisions is based.²

HISTORICAL ASPECT

Cast post and cores were the standard for many years and are still used by some clinicians.⁴ Steele in 1973 suggested the concept of supporting an endodontically treated tooth using a reinforced composite resin foundation with an internal “crutch” to combat horizontal forces.⁵ In 1975

Stahl and O'Neal suggested the composite resin dowel and core as a practical alternative to the cast gold dowel and core.⁶ Use of zirconia to construct endodontic posts was described in 1994. Carbon fiber posts were introduced by Duret et al in 1996.⁷ Now a days, other types of fiber posts also are available, including quartz fiber, glass fiber, and silicon fiber posts. They are claimed to offer the same advantages as the carbon fiber posts, but with better esthetics.⁴

POST PLACEMENT INDICATIONS

The decision regarding post placement should be made according to position of the tooth in the arch, the amount of coronal remaining tooth structure and the functional requirements of the tooth.

Posterior teeth

If an endodontically treated premolar has increased functional stresses acting on the crown due to loss of the periodontium and is to serve as an abutment for a removable partial denture, a post may be indicated. Unless a large percentage of coronal tooth structure is missing, posts are rarely required in endodontically treated molars.²

Anterior teeth

Because of the shearing forces (off axis loading) that act on them, anterior endodontically treated teeth are restored with posts more often than posterior teeth. When there is no functional or

aesthetic requirement for a full-coverage restoration, a post is not indicated.²

DOWEL AND CORE SELECTION

Many factors affect the selection of a particular dowel and core system for tooth restoration. Two variables that have a major influence are: amount of remaining tooth structure and functional stresses anticipated for the tooth. Other factors are: Root length, Tooth anatomy, Post width, Canal configuration and post adaptability, Role of hydrostatic pressure, Post design, Post material, Material compatibility, Bonding ability, Core retention, Retrievability and Esthetics.⁸

IMPORTANT PRINCIPLES FOR POSTS

Conservation of Tooth Structure

In creating post space, only minimum tooth structure from the canal is removed. Adequate apical seal, minimal canal enlargement, adequate post length, positive horizontal stop (to minimize wedging), vertical walls to prevent rotation and extension of the final restoration margin onto sound tooth structure are six important features for successful design.

Retention Form

Post length, post diameter, post design, luting agents, luting method, canal shape, preparation of canal space and tooth and location in the dental arch are factors affecting retention. Retention increases as the post length increases but too long may damage the seal of the root canal filling. Most endodontic texts advocate maintaining a 5-mm apical seal. However, if a post is shorter than coronal height of the clinical crown of the tooth, the prognosis is considered to be unfavourable, because stress is distributed over a smaller surface area, thereby increasing the probability of root fracture. In case of a short root and a tall clinical crown, an apical seal of 3 mm is considered acceptable. Adequate width of the post is important for post strength and resistance to post fracture.

Several studies have reported that a well-adapted, passively luted, parallel-sided post provided the most retentive post with the least stress. A serrated or roughened post is more retentive than a smooth one and controlled grooving of the post and root canal considerably increases the retention of a tapered post.

Resistance Form

Resistance refers to the ability of the post and tooth to withstand lateral and rotational forces. It is influenced by the remaining tooth structure, the post's length and rigidity, the presence of anti-rotation features and the presence of a ferrule.⁹

POST CLASSIFICATION

Posts can be classified as: prefabricated post and custom-made post. Prefabricated posts further classified as metal prefabricated posts made up of gold alloy, high platinum alloys, Co-Cr-Mo alloys, Stainless steel, Titanium and titanium alloys. Other prefabricated posts are carbon fiber post, quartz fiber post, zirconia posts, glass fiber post and plastic posts. Custom made posts can be cast from a direct pattern fabricated in patient's mouth or indirect pattern fabricated in the lab. Custom cast metal post and core made up of: gold alloys, platinum-palladium alloys, base metal alloys, Co-Cr-Mo alloys, Ni-Cr alloys. Posts can also be classified as: active posts and passive or cemented posts. According to post design, posts can be smooth, parallel sided, serrated, and tapered.¹⁰⁻¹²

PREPARING THE POST SPACE

Preservation of radicular dentin is important, so there should be minimal enlargement of the canal beyond the shape that was developed during root-canal instrumentation.⁴ Gutta-percha can be removed using any of the following three methods: Chemical removal - Solvents such as oil of eucalyptus, oil of turpentine and chloroform have been used to soften gutta-percha for removal, with the latter two being the most efficient. The use of chemicals for gutta-percha removal should be discouraged. Containment of the chemical within the canal and total control to the desired depth are very difficult.

Thermal removal - A heated instrument such as a lateral compactor can be inserted into the gutta-percha to the desired length to soften and remove the guttapercha. However, in narrow canals, fine instruments lose their heat quickly and gutta-percha removal can be difficult. A System B spreader is ideal for removal of gutta-percha (Fig.1). An instrument such as a Buchanan plugger (Fig. 2) can then be used to vertically compact the softened gutta-percha. Such a technique is useful in removing old gutta-percha which can become quite hard.

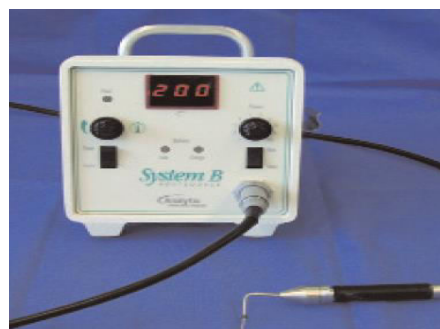


Figure 1: System B with heated plugger (200°C)

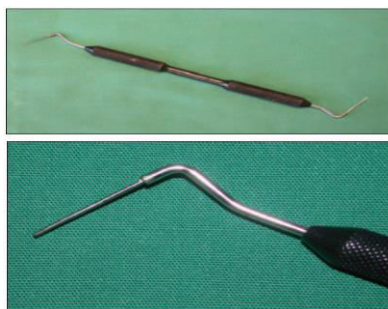

Figure 2: Buchanan plugger

Mechanical removal – This is an efficient and probably the most commonly used technique, but it is a technique that can result in the most damage to tooth tissue. A non-end cutting bur such as a Gates-Glidden or Peeso reamer should be used for gutta-percha removal, as these will cut and remove the relatively softer gutta-percha preferentially to the dentine of the canal walls.¹³

Four to 5 mm of gutta percha should be retained apically to ensure an adequate apical seal.⁴

LUTING CEMENTS

Any of the current luting cements can be used successfully with a post if the proper principles are followed. The most common luting agents are zinc phosphate, resin, glass ionomer, and resin modified glass-ionomer cements. The recent trend has been toward resin cements, because they increase retention.⁴ Light cured resin cements, dual cured resin cements and auto cured resin cements are the different types of resin cements available.¹⁴

CORE FABRICATION

After the dowel is luted to the root any necessary retentive and antirotation mechanisms are added. The minimal number of additional retentive devices should be used, as these pins, grooves, and other dentin preparations remove tooth structure. Often the undercut nature of the remaining pulp chamber, the irregularity of the residual coronal tooth structure, and the angle at which the dowel exits the tooth are adequate to ensure core retention. These features, along with normal irregular cervical root anatomy, provide adequate antirotation to most restorations. The core material is then placed around the dowel, into the remaining

pulp chamber, and built up to form the coronal restoration.¹⁵

CONCLUSION

If certain basic principles are followed in the restoration of endodontically treated teeth, it is possible to achieve high levels of clinical success with most of the current restorative systems.

REFERENCES

1. Lovdahl PE, Nicholls JJ. Pin retained amalgam cores vs. cast gold dowel cores. *J Prosthet Dent.* 1977;38(5): 507-14.
2. Rubina, Kumar M, Garg R, Saini R, Kaushal S. Prosthodontic management of endodontically treated teeth – a review. *Int Dent J Student's Research.* 2013;1(4): 4-12.
3. Patel SS, Shah DN. Restoration options with posts and cores. *J Ahm Dent Coll Hos* 2013;4(1):10-14.
4. Gupta A, Nagrani K. Management of endodontically treated teeth part-2. *Guident.* July 2013: 32-6.
5. Steele GD. Reinforced composite resin foundations for endodontically treated teeth. *J Prosthet Dent* 1973;30:816-819.
6. Stahl GJ, O'Neal RB. The composite resin dowel and core. *J Prosthet Dent* 1975; 33: 642-648.
7. Stewardson DA. Non-metal post systems. *Dent Update* 2001;28:326-336.
8. Fernandes SA, Shetty S, Coutinho I. Factors determining post selection: A literature review. *J Prosthet Dent.* 2003;90: 556-62.
9. Rubina, Kumar M, Garg R, Saini R, Kaushal S. Prosthodontic management of endodontically treated teeth – a review. *Int Dent J Student's Research.* 2013;1(4):4-12.
10. Garg N, Garg A. Textbook of endodontics. 2nd ed. New Delhi: Jaypee Brothers Medical Publishers; 2010
11. Weine FS. Endodontic therapy. 5th ed. St Louis: Mosby-year book; 1996
12. Kantorowicz GF, Howe LC, Shortall AC, Shovelton DS. Inlays, crowns & bridges a clinical handbook. 5th ed. USA: John Wright Publishing;1993.
13. Ricketts DNJ, Tait CME, Higgins AJ. Tooth preparation for post-retained restorations. *Br Dent J.* 2005;198(8): 463-70.
14. Dehghan M, Braxton AD, Simon JF. An overview of permanent cements. *Inside Dentistry* 2012;8(11): 1-4
15. Cohen S, Hargreaves KM. Pathways of the pulp. 9th ed. Missouri: Elsevier Publishers; 2006.

Source of support: Nil

Conflict of interest: None declared